



CASUISTIC PAPER

Miłosz Ambicki ^{1(ABCD FG)}, Robert Brodowski ^{1(BCD)}, Marta Mucha ^{1(FG)}, Małgorzata Migut ^{1,2(AFG)},
Adam Malawski-Róg ^{1(BCD)}, Wojciech Stopyra ^{1(BCDF)}, Bogumił Lewandowski ^{1,2(ABCD F)}

Drug-induced gingival overgrowth after cyclosporin A therapy

¹ Clinical Department of Maxillo-Facial Surgery, Frederic Chopin Provincial Specialist Hospital in Rzeszów

² Department of Emergency Medicine, Faculty of Medicine, the University of Rzeszów

ABSTRACT

Introduction. Drug-induced gingival overgrowth is a condition caused by side effects of treatment with one of three types of drugs: phenytoin (used in epilepsy treatment), cyclosporin A (used in transplantology after allogeneic organ transplants) and calcium channel blockers (in the treatment of hypertension). Gingival overgrowth leads to the development of inflammation within the gums and periodontium, reduced comfort in a patient's life, and consequently even loss of teeth.

Aim. The aim of this study was to present the issue of drug-induced gingival overgrowth based on a review of the literature and observations of patients treated in the Clinical Department of Maxillo-Facial Surgery, Frederic Chopin Provincial Specialist Hospital in Rzeszów.

Case description. Massive gingival overgrowth requires surgical management. Attention should be paid to multidisciplinary cooperation in case of patients qualified for a transplant. It is also important to qualify and evaluate the state of the oral cavity prior to the implementation of immunosuppressive medication, instruction of patients on oral hygiene and removal of the outbreaks of infection.

Keywords. drug-induced gingival overgrowth, cyclosporin a, gingivitis, transplant

Introduction

Gingival overgrowth is caused by both external as well as intrinsic etiological factors. Clinical symptoms include enlargement of the volume of the vertical and horizontal dimensions of the gingival margin and gingival papilla. It is the result of one of two distinct pathological processes. On the cellular level, it corresponds to a hypertrophy that causes overgrowth and enlargement in size and volume of individual cells without increasing their number, and hyperplasia – overgrowth, which leads to

enlargement of tissues or organs by increasing the number of cells. The clinical picture in both of these processes is similar. Histopathological examination allows us to discriminate between them. Overgrowth in the oral cavity may occur in the form of acute or chronic lesions. They may be focal, located only in the anterior or lateral portion of the gingival garland or have generalized character occupying significant part of the alveolar process of the maxilla and alveolar part of the mandible. Advanced lesions may include 1/3 of the tooth crown

Corresponding author: Bogumił Lewandowski, Department of Emergency Medicine, Faculty of Medicine, the University of Rzeszów

Participation of co-authors: A – Author of the concept and objectives of paper; B – collection of data; C – implementation of research; D – elaborate, analysis and interpretation of data; E – statistical analysis; F – preparation of a manuscript; G – working out the literature; H – obtaining funds

Received: 14.01.2017 | Accepted: 14.03.2017

Publication date: June 2017

Ambicki M, Brodowski R, Mucha M. *Drug-induced gingival overgrowth after cyclosporin A therapy.* *Eur J Clin Exp Med.* 2017;15(1):82–86. doi: 10.15584/ejcem.2017.1.13

height or over 1/2 of its size. Additionally, they can be complicated with the presence of plaque.^{1,2}

Initially, overgrowth lesions start in the area of the gingival margin and gingival papilla, then spread to the periodontium and the surrounding tissues. Apart from local factors such as tartar, plaque and bad hygiene, gingival overgrowth may result from side effects of drugs and chronic treatment.^{3,4}

Overgrowth and inflammatory gingival lesions may be caused by anti-epileptic drugs (Hydantoin derivatives), immunosuppressive drugs such as cyclosporin A, and drugs used in treatment of hypertension (calcium channel blockers). Drug-induced gingival overgrowth depends on the type of medication used, the age of the patient (more often in children and adolescents) and location (more often affects gums in the area of the front teeth) [3]. First symptoms appear about 3 months after the initiation of treatment with a given drug. Drug-induced gingival overgrowth is a multifactorial response. Local factors such as plaque and biofilm associated with about 750 types of bacteria aggravate the overgrowth and maintain inflammation.⁵⁻⁷

The pathomechanism of drug-induced gingival overgrowth is not fully explained and dependent on the type of medicine. In the case of hydantoin derivatives (used in the treatment of epilepsy), the intensification of the process is related to the metabolism of adrenal cortical hormones. Fibroblasts metabolize testosterone to 5-alpha-dihydrotestosterone. Chronic use of phenytoin increases the metabolic activity of the cell resulting in an increased production of collagen, inhibition of the activity of collagenase and tissue inhibitors of metalloproteinase.⁸ Genetic factors are also important – drugs that cause drug-induced gingival overgrowth are metabolized by cytochrome p450 enzymes, which are characterized by high genetic variability.⁹ Research on genes responsible for HLA leukocyte antigen coding confirmed the theory of HLA-DR2 antigen influence, which is found much more commonly in patients with moderate or severe drug-induced gingival overgrowth than HLA-DR1.^{10,11}

Cyclosporin A is a cyclic polypeptide (undecapeptide) isolated from the *Tolypocladium inflatum* fungus in the first phases of antibiotic research.

Due to its immunosuppressive activity, it was first used in patients in 1978 after kidney transplants as well as in the treatment of many conditions with autoimmune components.¹² The main indication for its use is prevention of rejection of allogeneic organ transplants. In vitro studies show that cyclosporine A causes increased collagen mRNA synthesis, in particular, pro collagen type 1. The main tissue metabolite of cyclosporin A, OL-17, reacts with fibroblasts thus leading to excessive cell proliferation and increased synthesis of proteins.^{9,13} The most commonly observed side effects during cyclospo-

rin therapy apart from gingival overgrowth include hirsutism, hand tremor, impaired renal function, hepatic dysfunction, gastrointestinal disorders and increase of blood pressure.¹⁴⁻¹⁶ Epidemiological and experimental studies have shown that combined cyclosporin A and nifedipine therapy may intensify gingival overgrowth. Nifedipine, which is often used in the treatment of hypertension, has an undesirable effect on the periodontium and gums as it can exacerbate gum overgrowth.⁵ The third group of drugs causing gingival overgrowth are calcium channel blockers (e.g. nifedipine, amlodipine, verapamil) used mainly in the treatment of hypertension. Patomechanism is related to inhibition of the transition of the cell to the state of apoptosis, which in consequence leads to macroscopic tissue hypertrophy. Calcium deficiency in epithelial cells leads to production of BCL2 protein inhibiting apoptosis and in excess, to the production of Bax protein acting in the opposite way.⁹

Treatment of drug-induced gingival overgrowth depends on the degree of progression of the disease. In most cases, conservative treatment is used. Conservative methods (mainly periodontal) are professional hygienisation procedures, use of local anti-inflammatory and antibacterial drugs, and dental plaque control by the patient. Some authors claim that these treatments allow for reduction of surgical treatment by up to 50%.¹⁷ Surgical methods are used in cases of advanced overgrowth that hinder nutrition, food intake, causing difficulties in speech and maintaining oral hygiene. These states are often associated with painful bleeding in the oral cavity and the occurrence of abscesses caused by the spreading infections. Surgical treatment eliminates completely the potential outbreak of infection in the oral cavity and allows forming a normal physiological gingival contour which consequently improves the hygiene and aesthetics of the oral cavity. It also has a positive effect on the well-being and quality of the patient's life after surgery. Gingival overgrowth treatment uses traditional surgical methods or methods applying modern techniques such as lasers, electric knives or cryotherapy.^{5,9,13}

In everyday practice, almost every doctor can encounter patients who use various chronic drug therapies, including more and more frequently, immunosuppressive treatment after organ transplants. An example of an immunosuppressive drug widely used in transplantology is cyclosporin A.

The aim of this study was to present the issue of cyclosporin A induced gingival overgrowth based on the observations of three patients recently treated after kidney transplant and a literature review as an example of oral complications. This issue seems interesting to most practitioners because of the interdisciplinary nature of the procedure.

Case I

The patient J.S. aged 68 was admitted to the Department of Maxillo-Facial Surgery, Frederic Chopin Provincial Specialist Hospital in Rzeszów due to massive gingival overgrowth complicated by chronic inflammation. During the interview it was found that the first limited gingival overgrowth appeared about 13 years before and it was characterized by slow growth. Overgrowth was accompanied by pain, problems with food intake, repeated bleeding, inflammation and pus effusion. It has been established during the interview that, since kidney transplantation, the patient has been using cyclosporin A for 13 years. His history included brain stem stroke 14 years before. He had type II diabetes and hypertension for several years. The oral examination revealed massive dark-pink gingival overgrowth in the upper dental arch in the area of teeth 17 to 27 (Figure 1a.) and the lower arch in the section of 36 to 46 covering more than half of the vertical dimension of teeth crowns (Figure 1)

In addition, pathological mobility of teeth 43, 44, 33, 34, 11, 13, 14, 15, 17, and 23 was found with abundant dental plaque and subgingival plaque. Teeth 26 and 27 did not show the characteristics of increased mobility. Pus content was present in the pathological periodontal pockets. Odor from the mouth (feter ex ore) was noticeable. The pantomogram revealed bone defects typical of advanced periodontium diseases affecting the alveolar

part of the maxilla and alveolar process of the mandible. The patient was qualified for removal of the pathological overgrowth of gingival tissues and local gingivoplasty, which consisted of modeling the alveolar process of the maxilla and the alveolar part of the mandible which enables future prosthetic treatment. The postoperative course was uneventful. Postoperative wounds healed correctly. Immediately after surgery the patient did not follow the medical recommendations to use products facilitating high level of oral hygiene. During subsequent outpatient inspections the patient was motivated to use and maintain proper oral hygiene. At the end of the treatment, despite the recommendations, the patient did not decide to make prosthetic restorations. The patient remained in outpatient follow-up for a period of 1 year. During follow-up after 3, 6 and 12 months after surgery no relapse was observed.

Case II

The patient M.M. aged 59 was admitted to Department of Maxillo-Facial Surgery, Frederic Chopin Provincial Specialist Hospital in Rzeszów due to the overgrowth of the lower gingiva. He did not report any pain. This patient was immunosuppressed with cyclosporin A for 13 years after kidney transplantation. During the interview he also reported treatment with nitrendibin for hypertension. He noticed gingival overgrowth about a year

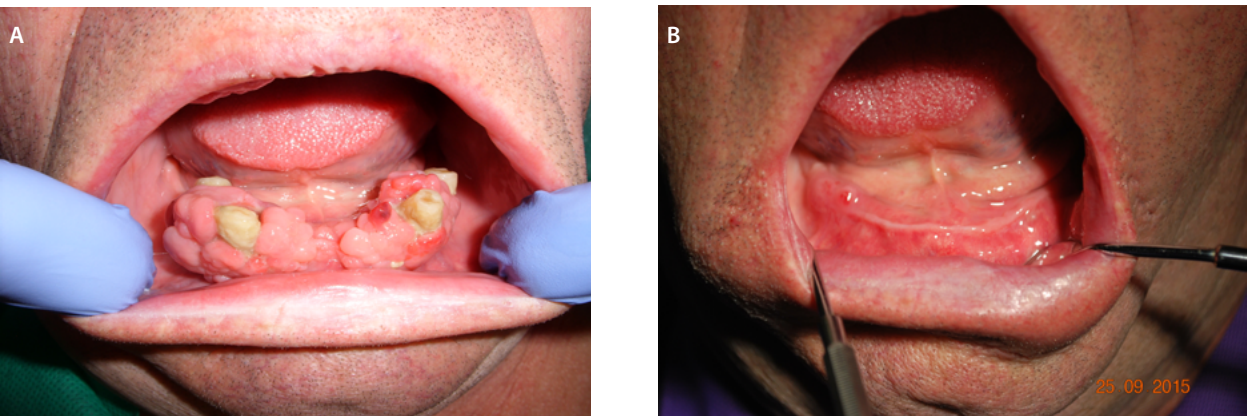


Figure 1. Patient J. S. Massive lower gum overgrowth (A). State after surgery (B).

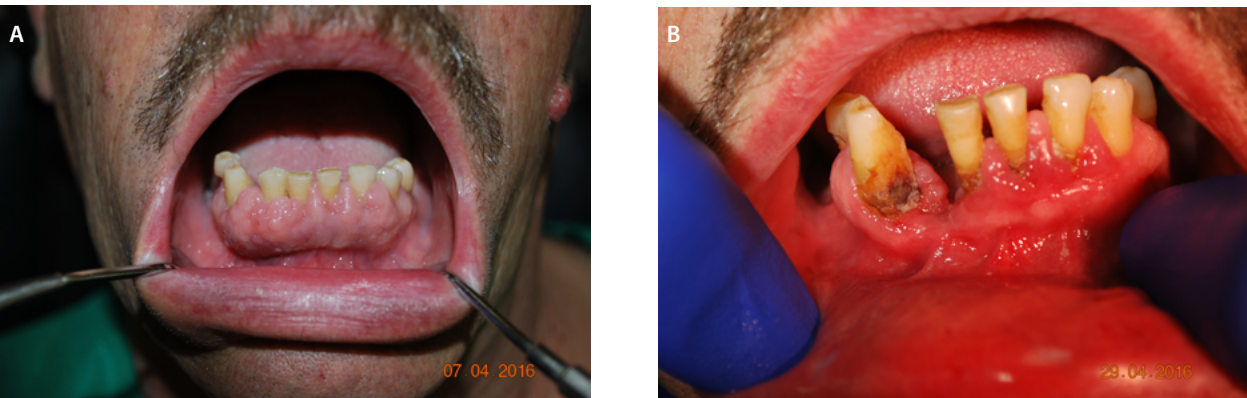


Figure 2. Patient M.M. Massive upper gum overgrowth. (A) – state before surgery, (B) – state after surgery

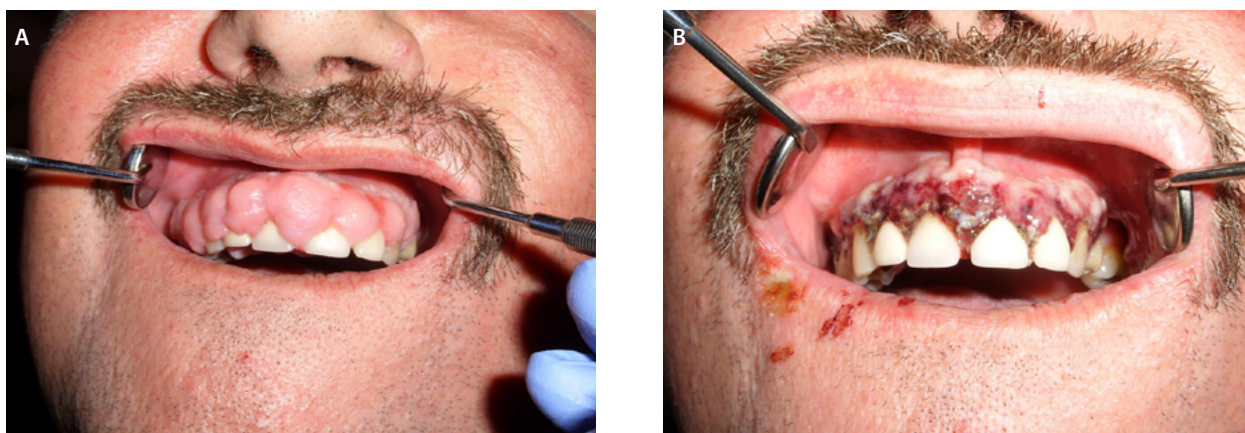


Figure 3. Patient P.K. Massive upper gum overgrowth. (A) – state before surgery, (B) – state after surgery – healing wounds

ago that coincided with an increased dose of cyclosporin A (125 mg to 340 mg/day). In addition, the patient was diagnosed with tuberculosis of the urinary tract. A clinical examination revealed the overgrowth of lower gingiva locally from 33–44 covering half the height of the teeth crown. No active inflammation was found. The panoramic X-ray revealed horizontal cavities of bone of the alveolar part of the mandible and the alveolar process of the maxilla characteristic of periodontal conditions. The patient was qualified for surgical removal of gingival overgrowth with gingivoplasty of the alveolar part of the mandible in sections 33–44. The surgery was planned in a way to ensure proper prosthetic restoration and rehabilitation of the chewing organs. The Patient postoperative course was uneventful. Wounds healed by granulation. No local recurrence was found at the follow up after 3 months, and after 1 year.

Case III

The patient P.K. aged 41 came to appointment at the Outpatient Maxillo-Facial Surgery Clinic due to fibro-nodular overgrowth of gingival papillas and gingiva covering the alveolar process of the maxilla observed for about 1 year. Swelling proceeded slowly up to the size that caused the patient concern. He did not observe any bleeding, inflammation and pain. According to the interview, he took the immunosuppressive drug cyclosporin A for 8 years due to renal transplant. During examination it was observed that overgrowth included 3 tooth crowns on the vestibulo-labial side and the hard palate causing not only difficulty in food intake and chewing but also disturbed his smile aesthetic. (Figure 3)

On the basis of history and physical examination, drug-induced overgrowth and nodular lesions within gingiva associated with cyclosporin A was diagnosed. The patient was qualified for the removal of overgrowth with gingival garland modeling under general anesthesia. The course of the treatment was uneventful. After the surgery, the patient reported pain which was relieved with analgesics. On the second day he was discharged

and referred for outpatient follow-up. Fig. 3B presents the local state after treatment during wound healing.

Conclusion

The mechanism of gingival overgrowth is not fully understood. Discontinuation of pharmacotherapy may cause local changes to regress, however, discontinuation of cyclosporin A therapy is not possible and its replacement with another immunosuppressive drug, e.g. tacrolimus, does not result in overgrowth regression. Special attention should be paid to the health of the oral cavity before starting cyclosporin or other immunosuppressant therapy.

The presence of periodontal conditions, their degree of their severity, poor oral hygiene, and the presence of caries, especially before cyclosporin therapy, predispose a patient for gingival overgrowth, which requires surgical treatment almost exclusively.

Multidisciplinary cooperation of transplantologists, dentists, periodontists and maxillofacial surgeons during both the pre and post-transplant period is necessary because it can reduce complications and side effects resulting from immunosuppressive treatment in patients after organ transplants.

Compliance with ethical standards

Conflict of interest: The authors declare that they have no conflicts of interest.

Funding: None

References

1. Lipska W, Gałęcka-Wanatowicz D, Chomyszyn-Gajewska M. Przerostowe zapalenie dziąseł – opis przypadków. *Implantoprotetyka*. 2009;4(37):44-7.
2. Radwan-Oczko M, Ziętek M, Boratyńska M, Konopka T. Stopień i rozległość przerostu dziąseł u chorych po przeszczepie nerki leczonych cyklosporyną A. *Czas Stomat*. 1996;49:824-9.
3. Jańczuk Z. *Praktyczna periodontologia kliniczna*. Warszawa:Kwintesencja;2004.

4. Wolf HF, Rateitschak EM, Rateitschak KH. *Periodontologia*. Warszawa:Czelej;2006.
5. Kowalski J. Lekopochodny przerost dziąseł – przegląd literatury. *Nowa Stomat*. 2010;4:180-2.
6. Seymour RA, Elis JS, Thomason JM. Risk factors for drug-induced gingival overgrowth. *J Clin Periodontol*. 2000;27:217-23.
7. Gaphor SM, Abdulkareem SA, Abdullah MJ. Cyclosporine induced gingival hyperplasia in kidney transplant: a case report and review of the literature. *European Scientific Journal*. 2014;10(15):413-8.
8. Seymour RA, Thomason JM, Ellis JS. The pathogenesis of drug-induced gingival overgrowth. *J Clin Periodontol*. 1996;23:165-75.
9. Gonzales FJ. Human cytochromes p450: problems and prospects. *Trends Pharmacol Scienc*. 1992;13:346-52.
10. Tyrzyk S, Sadlak-Nowicka J, Bochniak M, Kędzia A, Szumska-Tyrzyk B, Rutkowski P. Obraz kliniczny, radiologiczny i bakteriologiczny przyzębia u chorych leczonych cyklosporyną A po przeszczepie nerki. *Dent Med Probl*. 2002;39(1):55-62.
11. Olczak-Kowalczyk D, Bedra B, Śmirska E, Pawłowska J, Grenda R. Zmiany w jamie ustnej u pacjentów po transplantacji narządów unaczynionych w zależności od rodzaju stosowanej immunosupresji – badanie pilotażowe. *Czas Stomatol*. 2006;11:759-68.
12. Marshall RI, Bartold PM. Medication induced gingival overgrowth. *Oral Disease*. 1998;4:130-51.
13. Vescovi P, Meleti M, Manfredi M, Bonanini M. Pathogenesis of cyclosporin induced gingival overgrowth. *Min Stomatol*. 2003;52:219-29.
14. Ciavarella D, Guiglia R, Campisi G, et.al. Update on gingival overgrowth by cyclosporine A in renal transplants. *Med Oral Patol Cir Bucal*. 2007;12:19-25.
15. Węgorska D, Syryńska M. Przerosty dziąseł – Gingivitis hyperplastica – jako efekt uboczny leczenia cyklosporyną A (CsA, CyA0). *Magazyn Stomat*. 1994;4(1):18-21.
16. Prajs K, Fliciński J, Przepiera-Będzia H, Brzosko I, Ostaniek L. Działania niepożądane w czasie leczenia cyklosporyną A u chorych na reumatoidalne zapalenie stawów – obserwacje własne. *Roczniki Pomorskiej Akademii Medycznej w Szczecinie*. 2010;56(1):48-51.
17. Camargo PM, Melnick PR, Pirih FQ, Lagos R, Takei HH. Treatment of drug-induced gingival enlargement: H. Aesthetic and functional considerations. *Periodontology*. 2001;27:131-8.