






CASUISTIC PAPER

Berrin Erok ¹(ABCFG), Nu Nu Win ²(CFG), Sertaç Tatar ¹(BG)

Pericallosal berry aneurysm associated with azygous anterior cerebral artery – a case report

¹ Department of Radiology, University of Health Sciences, Prof Dr. Cemil Tascioglu City Hospital, Istanbul, Turkey

² Department of Radiology, Bahcelievler Medica Hospital, Istanbul, Turkey

ABSTRACT

Introduction. Azygos anterior cerebral artery is a rare variant of the anterior segment of the circle of Willis caused by an unusual fusion of the normally paired A2 segments of the anterior cerebral artery (ACA). Despite its rare occurrence, it is associated with various vascular and structural cerebral abnormalities, particularly berry aneurysms.

Aim. We aimed to present a case of a 41-year-old female patient who presented to our neurology department with complaints of headache.

Description of the case. She had a positive paternal history of aneurysmal subarachnoid hemorrhage. Magnetic resonance angiography (MRA) of her brain revealed an azygos ACA (bifurcating into two pericallosal arteries) which was associated with a saccular aneurysm at its bifurcation point. She was referred to the interventional radiology department for preventive endovascular treatment.

Conclusion. Azygos ACA carries a high risk of aneurysm development and its occlusion can potentially compromise blood supply to both cerebral hemispheres. It is therefore crucial for clinicians to be aware of its significance and to report its presence in angiographic studies.

Keywords. azygos ACA, berry aneurysm, magnetic resonance angiography

Introduction

Azygos anterior cerebral artery (ACA) is a variant of the anterior segment of the circle of Willis characterized by a single A2 segment, in which both ACA territories are supplied by this single A2 trunk. The underlying pathological mechanism is the persistence of embryonic median artery of the corpus callosum.¹ It was first described by Wilders, as *arteria termatica*.² It is a rare variation of the ACA with an incidence of about 0.4-1% in

the general population.³ There are different branching patterns of this variation. More frequently it divides into two pericallosal arteries, but it may also trifurcate into two pericallosal arteries and one callosomarginal artery or quadrifurcate into two pericallosal arteries and two callosomarginal arteries.^{4,5} Despite its rare occurrence, it is associated with various vascular and structural cerebral abnormalities, particularly berry aneurysms.

Corresponding author: Berrin Erok, e-mail: drberrinerok@hotmail.com

Participation of co-authors: A – Author of the concept and objectives of paper; B – collection of data; C – implementation of research; D – elaborate, analysis and interpretation of data; E – statistical analysis; F – preparation of a manuscript; G – working out the literature; H – obtaining funds

Received: 28.02.2021 | Accepted: 27.05.2021

Publication date: June 2021

Erok B, Win NN, Tatar S. *Pericallosal berry aneurysm associated with azygous anterior cerebral artery – a case report*. *Eur J Clin Exp Med*. 2021;19(3):259–261. doi: 10.15584/ejcem.2021.3.9.



Aim

We aimed to present a case of an azygos ACA bifurcating after a segment of a common trunk and having an aneurysm at this bifurcation point.

Description of the case

A 41-year-old female patient presented to our neurology department with complaints of headache of increasing frequency and severity. She had a positive paternal history of aneurysmal subarachnoid hemorrhage. On magnetic resonance angiography (MRA) of the brain, an azygos ACA bifurcating into two pericallosal arteries after a 7 mm segment of the fused azygos trunk was established. There was a 4x3.7 mm sized saccular aneurysm projecting antero-superiorly at this bifurcation point (Figure 1). There was no ACoA as expected, but the rest of the circle of Willis was unremarkable. She was referred to the interventional radiology department for preventive endovascular treatment.

Discussion

Azygos ACA is one of the clinically important anomalies of the circle of Willis, because its occlusion affects both hemispheres. On the other hand, cerebral aneurysms are frequent with a reported incidence varying between 13 to 71% (2), which is very high when compared with the reported incidence of cerebral aneurysms (0.2-8.9) in the unaffected general population.⁶ In a review of 36 cases of distal ACA aneurysms, 6 cases (17%) were associated with azygos ACA.⁷ In another study including 105 patients with subarachnoid hemorrhage, among 8 cases of distal ACA aneurysms, 2 (1.9%) cases were associated with azygos ACA with the incidence rate of 25%.⁸ The typical location for aneurysm

development is at the bifurcation point of the common trunk, likely due to alterations in the hemodynamics at this site. Congenital abnormalities in the vessel walls may also be contributory to the development of azygos ACA aneurysms.

Although the rest of the circle of Willis was unremarkable in our patient, other vascular anomalies or variations may also be associated with azygos ACA. These include absence of the anterior communicating artery (ACoA) as in our case. In a retrospective study by Beyhan et al. including a total of 4913 cases who had brain computed tomography angiography (CTA), MRA, contrast-enhanced magnetic resonance imaging (MRI) and digital subtraction angiography (DSA), azygos ACA was observed in 57 cases with the frequency of 1.16%. In this study, unilateral vertebral artery hypoplasia and ACA A1 segment hypoplasia were the most common associated vascular variations.⁹ Although not present in our patient, as a midline vascular variation, azygos ACA is more frequent in patients with various other midline abnormalities including dysgenesis of corpus callosum, lobar holoprosencephaly or septo-optic dysplasia.¹⁰

Conclusion

Azygos ACA is a rare but clinically important anomaly of the circle of Willis, with a high risk of aneurysm development which can sometimes be established incidentally on neuroimaging studies. It is noteworthy that its occlusion can potentially compromise blood supply to both cerebral hemispheres. Therefore, it is crucial for clinicians to be aware of its significance and to report its presence in angiographic studies.

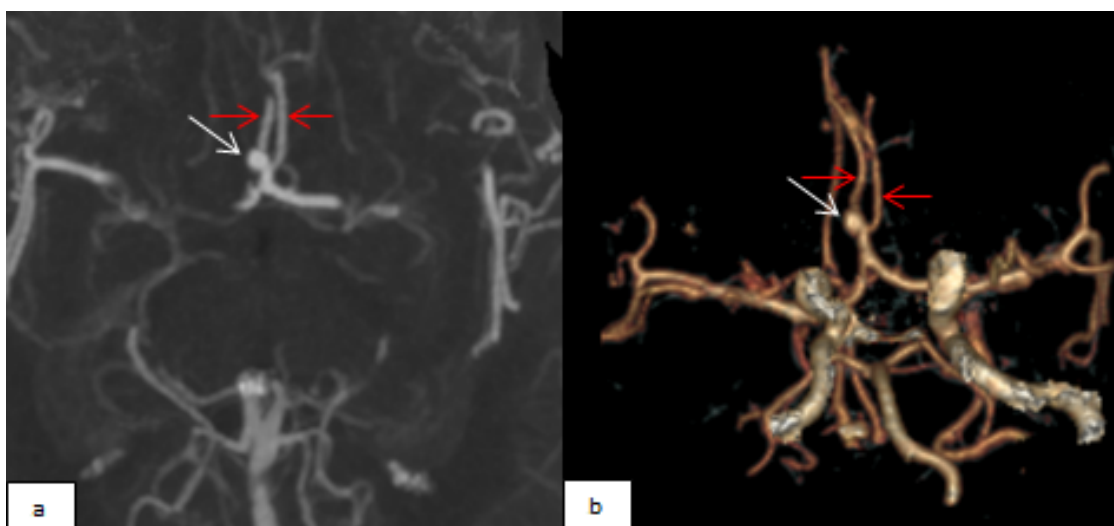


Fig. 1. Coronal maximum intensity projection image (A) and three-dimensional reformatting image (B) of contrast-enhanced MRA showing a saccular aneurysm projecting antero-superiorly (white arrows) from the bifurcation point of the azygos ACA. Two pericallosal arteries are shown (red arrows). There is no ACoA

References

1. Dimmick SJ, Faulder KC. Normal variants of the cerebral circulation at multidetector CT angiography. *Radiographics*. 2009;29(4):1027-1043.
2. Schick RM, Rumbaugh CL. Saccular aneurysm of the azygos anterior cerebral artery. *AJNR Am J Neuroradiol*. 1989;10(5):73.
3. Huh JS, Park SK, Shin JJ, et al. Saccular aneurysm of the azygos anterior cerebral artery: three case reports. *J Korean Neurosurg Soc*. 2007;42(4):342-345.
4. Kaspera W, Ładziński P, Słowiński J, et al. Blood flow velocity in the arteries of the anterior cerebral artery complex in patients with an azygos anterior cerebral artery aneurysm: a transcranial color-coded sonography study. *Clin Neurol Neurosurg*. 2009;111(1):63-68.
5. Singh H, Dhandapani S, Mathuriya SN. Types of Azygos Distal Anterior Cerebral Artery Branching Patterns: Relevance in Aneurysmal Surgery. *Cureus*. 2016;8(7):e681.
6. Takahashi S. *Neurovascular Imaging, MRI & Microangiography*. Springer Verlag. 2010.
7. Katz RW, Horoupian DS, Zingesser L. Aneurysm of azygos anterior cerebral artery. A case report. *J Neurosurg*. 1978;48(5):804-808.
8. Ghanta RK, Kesanakurthy MV, Vemuri VN. Aneurysm of azygos anterior cerebral artery: A report of two cases. *Asian J Neurosurg*. 2016;11(3):312.
9. Beyhan M, Gökçe E, Karakuş K. Radiological classification of azygos anterior cerebral artery and evaluation of the accompanying vascular anomalies. *Surg Radiol Anat*. 2020;42(11):1345-1354.
10. Szdzuy D, Lehmann R, Nickel B. Common trunk of the anterior cerebral arteries. *Neuroradiology*. 1972;4(1):51-56.