








## CASUISTIC PAPER

Barbara Cyran-Grzebyk <sup>1(ABDEF)</sup>, Magdalena Szczepanik <sup>1(BCH)</sup>,  
Joanna Majewska <sup>1(CDE)</sup>, Katarzyna Bazarnik-Mucha <sup>1(FG)</sup>, Sławomir Snela <sup>1,2(A)</sup>

# Multistage treatment of a patient with developmental dysplasia of the hip: A case study

<sup>1</sup> Institute of Physiotherapy, Faculty of Medicine, University of Rzeszow, Rzeszow, Poland

<sup>2</sup> Orthopedics and Traumatology Clinic for Children and Adults, Clinical Hospital No. 2, Rzeszow, Poland

## Abstract

**Introduction.** Developmental dysplasia of the hip (DDH) concerns about 5 per cent of the newborn population, and congenital hip dislocation (1%) is considered a challenge in child orthopedics due to the risk of further complications. Recently, the occurrence of this illness has been decreasing due to early hip diagnostics in newborns and fast implementation of proper treatment.

**Aim.** To describe multi-annual treatment and multiplicitous complications in a 15 years old patient diagnosed with DDH.

**Description of the case.** Complications occurring, despite the treatment conducted in accordance with accepted standards, induced the necessity of surgical procedures. This paper describes applied surgical techniques, physiotherapy treatment, the functional status of patient during particular stages of treatment as well as current results of gait analyses.

**Conclusions.** In spite of early diagnosis and treatment of DDH, surgical intervention does not always bring the expected result.

**Keywords.** developmental dysplasia of the hip, complications, gait assessment, pelvic osteotomy

## Introduction

Developmental dysplasia of the hip (DDH) is considered the most frequent disorder of motor organs in Poland (it affects 4-6 % of infants). Early diagnostics of hip joints in newborns and infants as well as swift implementation of proper treatment significantly decreases the frequency of total luxation (dislocation) that requires surgical intervention.<sup>1-4</sup> Available literature widely describes the risk factors of congenital defects of hip joint, treatment possibilities, complications and secondary effects including joint mobility limitations, necro-

sis of blood vessels within the head of femur (5-15% of cases), secondary dislocation of the joint and hip arthritis.<sup>4,5</sup> Early diagnosis and undertaking the proper treatment are the most important factors in preventing subsequent pathological changes.

Despite the fact that DDH is considered one of the most researched diseases, there are still many controversies regarding its etiology, diagnostics and treatment. One of them considers the timing of surgical treatment initiation in late diagnosed DDH in infants aged 6-8 months.<sup>6</sup> Some doctors recommend to start the treatment as soon as the disease is diagnosed, due to joint

**Corresponding author:** Barbara Cyran-Grzebyk, e-mail: [cantalupa@poczta.onet.pl](mailto:cantalupa@poczta.onet.pl)

**Participation of co-authors:** A – Author of the concept and objectives of paper; B – collection of data; C – implementation of research; D – elaborate, analysis and interpretation of data; E – statistical analysis; F – preparation of a manuscript; G – working out the literature; H – obtaining funds

Received: 28.06.2018 | Accepted: 28.09.2018

Publication date: December 2018

plasticity, as the joints of infants are mainly built from cartilage which ensures better modeling capabilities.<sup>7,8</sup> On the other hand, many orthopedists claim that the treatment should be undertaken after the appearance of ossification nucleus of femoral head, to decrease the risk of development of necrosis of femur.<sup>4,8,9</sup>

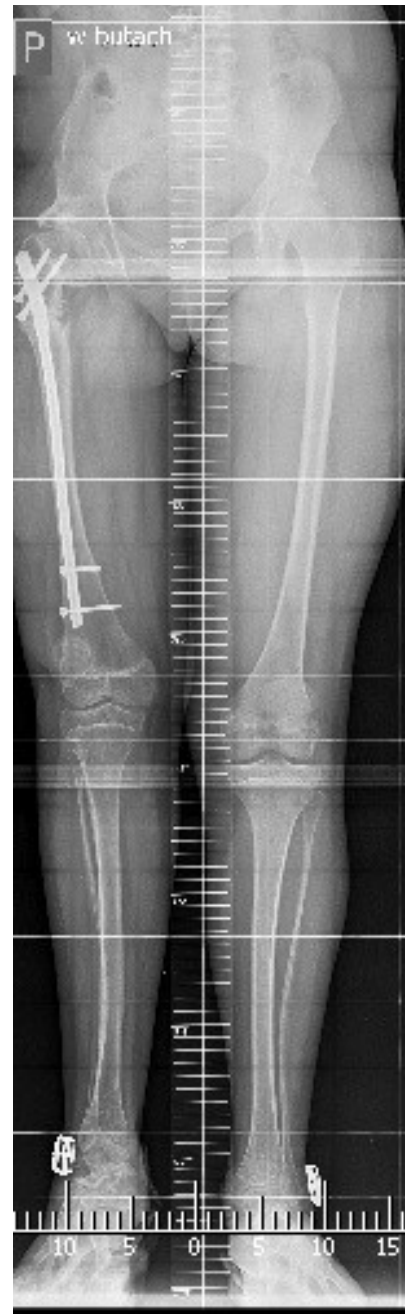Early diagnosis and treatment of DDH in newborns and infants enables application of nonsurgical treatment methods such as orthopedic appliances, over head extension and plaster casts.<sup>10</sup> Still, the optimal treatment result is not always obtained and treated infants remain with so called residual dysplasia.

### Case study

A 14 year old patient accompanied by guardians was admitted to the Children's Orthopedic Clinic with significant right lower limb shortening (PKD) of about 6.5 cm due to congenital DDH and multiple surgeries of the pelvis and right femur. The girl, a third child pregnancy was born naturally in good general condition (Apgar 9), weight – 2390 g, with no complications during the perinatal period. Right, total DDH was diagnosed in the first month of her life and the treatment was undertaken in the second month. The family history did not show any cases of dysplasia or DDH. Over next 14 years, the patient was hospitalized 16 times due to treatment of motor organs undertaking 13 surgical procedures on the pelvis and right lower limb with several complications such as reoccurring threefold joint luxation, delayed bone union after femur osteotomy, displacement of bone fragments, fracture of internal stabilization and contractures in right lower limb joints. Up to the age of 5, the patient was treated orthopedically without any physiotherapy treatment. After twofold luxation and subsequent surgery of right hip, post - surgery and ambulatory physiotherapy was applied. Such a treatment regimen for this patient was systematically continued from the age of 8.

In 2016, at the age of 13, the patient underwent right femur lengthening with the use of a monotube apparatus. Before that procedure, orthopedic and physiotherapy examination showed a right lower limb shortening of 6.5 cm with active and passive movement limitations of the right hip. ROM of abduction and adduction amounted to 20-0-25 with passive mobility of 25-0-25, ROM of active flexion and extension equaled 20-0-25 with passive mobility of 25-0-25, ROM of flexion and active extension 10-0-120 with passive mobility of -5 -0-110, ROM of hip rotation was difficult to assess while ROM of active flexion and extension of knee joint totaled -5-0-125 with passive mobility of -5-0-130. The right lower limb muscle strength assessed in Lovett scale was weak. Right hip joint flexors produced the result of 4+ while extensors 3, abductors 2+ and adductors 5. Additionally, the quadriceps femoris atrophy (2.5 cm dif-

ference while compared with left thigh) was noticed. For about a year the patient has been walking without elbow crouches while the limb shortening was compensated by orthopedic insole and shoe lining. Gait phases were incorrect showing waddling gait and positive Trendelenburg-Duchenne symptom. The patient also showed functional shortening of her Achilles tendon on the right side and fixed diagonal pelvis and lumbar spine position. After orthopedic examination and image diagnostics (Fig. 1), the patient was qualified for right lower limb lengthening.



**Fig. 1.** X-ray of the patient's silhouette on admission to orthopedic clinic for assessment of the length difference in lower limb before the application of Monotube apparatus (May 25<sup>th</sup> 2016)

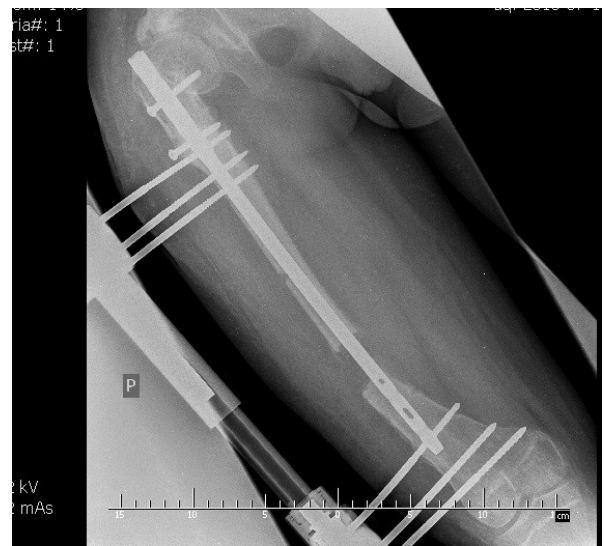### Surgical techniques

The patient has been treated from the age of 1 month, at first with conservative treatment with the use of overhead extension. Five weeks later, unsuccessful closed reposition of hip with arthrography was performed, followed by open, simple hip joint reposition and “human position” plaster cast. At the age of 5 the girl underwent reposition and reconstruction of right hip with osteotomy stabilized with Kirschner wires and plate due to joint luxation followed by hip plaster cast. One year later, the arthrography of right hip was performed and internal fixation (Kirschner wires) was removed from ala of ilium. At the age of 8 the luxation of the operated joint reoccurred. Subsequent surgery was necessary and the following procedures were applied: the plates and screws were removed, valgus osteotomy of femur was performed, stabilization with PHP plate was done and pelvis osteotomy according to Dega with the use of allogenic bone graft was performed. Three years later, the third right hip joint luxation occurred. The plates were removed, open reposition of hip was performed, valgus osteotomy of proximal femur with its shortening was done with PHP plate stabilization, pelvis osteotomy according to Dega was performed and hip plaster cast was applied. In the same year, due to delayed femur bone union, Gravitational Platelet Separation System (GPS) factor was applied. The patient continued physiotherapy including gait learning without weightbearing on right lower limb. At the age of 12 the subsequent complication occurred in the shape of fracture of internal implants. The subsequent surgery of proximal femur was performed; PHP plate and fractured implants were removed and intramedullary stabilization of subtrochanteric area was performed with the use of aLFN Expert blocked nail. With doctor’s permission, gradual weightbearing of right lower limb was started (February 2015). One year later, due to an increasing length difference of right lower limb (shortening of about 6.5 cm) the external Monotube apparatus was put on. During the lengthening process, the dislocation of bone fragments in sagittal plane occurred.

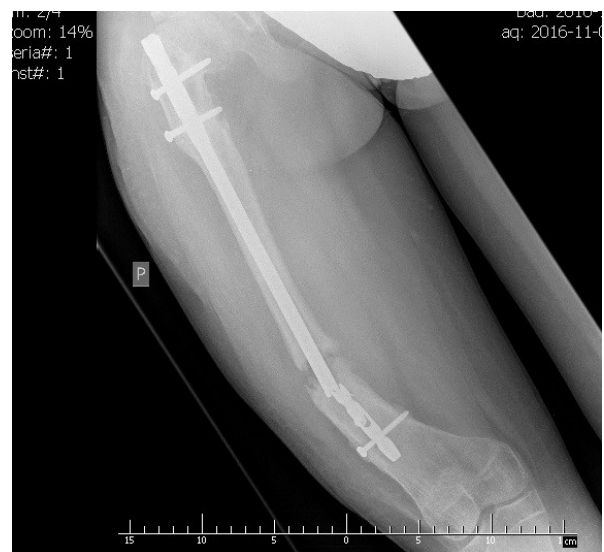The Monotube apparatus was urgently repositioned what led to its earlier removal with simultaneous blockage of nail in distal femur (Fig 2). As a consequence, the lengthening of 4 cm was obtained. Orthopedic and functional examination showed the following: decrease of muscle strength of right lower limb and pelvis, the need to use elbow crutches while walking, passive and active limitation of ROM of hip and knee joints.

After the consultation with the doctor, the patient participated in kinesiotherapy to minimize post-surgery effects in motor organ. Three months after the removal of apparatus (age 14), the intramedullary nail in distal femur got broken (Fig. 3). The nail was urgently removed and reposition of fracture with SYNTHES intramed-

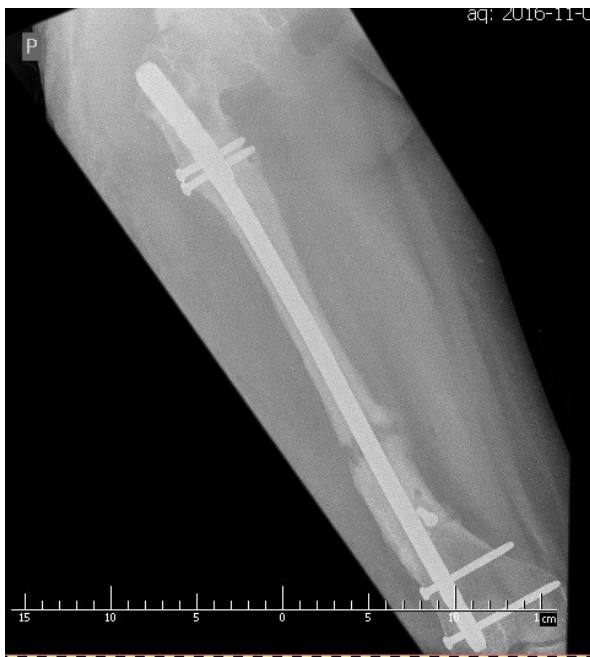ullary nail was performed (Fig. 4). The physiotherapy was continued and included anti-swelling exercises increasing active and passive ROM of joint of right lower limb and improving strength of gluteal muscles, teaching gradual weight bearing of the limb, gait learning (with insole compensating the length difference), knee-cap mobilization, stretching of quadriceps and hip joint adductors and posture control exercises. After 5 months the achieved ROM of hip joint was the same as before the use of Monotube apparatus. The only differences concerned the limitations of active ROM of knee joint -5-0-118, passive 0-0-125. Meanwhile, the control X-Ray done 3 months after the surgery confirmed proper course of treatment and stability of bone fragments.



**Fig. 2.** X-ray of right femur before the removal of Monotube apparatus ( June 13<sup>th</sup> 2016).



**Fig. 3.** Fracture of intramedullary osteosynthesis (November 3<sup>rd</sup> 2016)



**Fig. 4.** X-ray after the replacement of broken intramedullary nail with SYNTHES (November 11<sup>th</sup> 2016)

At the age of 15, 6 months since the last surgery, the girl has not been feeling any pain or unwellness. ROM of hip and knee joints are the same like before the lengthening process and muscle strength improved what made hip joint stability better and positively influenced the gait of the patient. Despite the difference in length of limbs, the girl started exercising on an exercise bike and learning how to walk with full weight bearing of right lower limb. Her quality of life has improved dramatically, as well as her balance and gait, however still done with the use of elbow crouches, what justifies the continuation of further physiotherapy

### Lab gait analyses

In order to assess the gait pattern of patient, the gait analyses with the use of BTS Smart was conducted in May 2017. The analyses showed weight bearing asymmetry of both limbs, the duration of stance phase was shorter on operated limb – 58.7% of gait cycle, compared with healthy -66% of gait cycle. The significant decrease of gait pace was also noticed (Tab. 1). The pelvis of patient was set up in anteversion of 9-15° and tilted in relation to gait direction. Its right side was positioned frontally, diagonally and upward (Fig. 5). During all gait cycles both hip joints were abducted. Left hip joint was internally rotated while the right one (operated) was externally rotated up to 50% of stance and at the end of terminal swing. Diagonal position of pelvis imposed excessive flexion of hip and knee joints as well as excessive dorsiflexion of the left foot in whole gait cycle (Fig. 5). The right foot was touching the surface with forefoot. At the beginning and the end of swing phase, right

foot was positioned in plantarflexion while in the mid swing in dorsiflexion up to 4 degrees. Left foot during whole swing phase was in dorsiflexion up to 12 degrees. In stance, right foot was externally over rotated up to 25 degrees while the left one was properly positioned in regard to gait direction.

**Table 1.** Summary of temporo-spatial gait parameters of patient

Temporo-spatial parameters	Operated limb		Non-operated limb	
	Value	SD	Value	SD
Stane phase [%]	58.7	0.6	66	0.3
Swing chase[%]	41.2	0.6	34	0.3
Step length [m]	0.49	0.02	0.48	0.01
	Value		SD	
Initial double support [%]	12.1		0.4	
Terminal double support [%]	12.1		0.9	
Cadence [step/min]	110.4		1.2	
Mean Speed [m/s]	0.67		0.04	

### Discussion

According to recommendation of Children Orthopedics Division of Polish Orthopedics and Traumatology Association, the compulsory standard to detect congenital defects of hip joint in children is their clinical examination and USG evaluation. The screening program of hip joints conducted in pre-luxation clinics considerably lowered the percentage of late diagnosis of hip dysfunctions. The majority of unstable hips get stabilized by themselves by 2-6 week of life while every hip that remains luxated or unstable requires immediate orthopedic intervention.<sup>12,13</sup> The infants under 6 months are being treated by not-surgical methods.<sup>13,14</sup> The lack of effectiveness of conservative treatment and late diagnosis of DDH impose the necessity to apply surgical methods including closed reposition of hip joint followed by “human position” cast and in older children open reposition and joint stabilization.<sup>16</sup> In children aged 18-24 months additional osteotomy of femur and/or pelvis is often required.<sup>6,16</sup> In hereby case study, considerable number of complications occurring despite the treatment conducted in accordance with standards imposed the necessity of surgical interventions. Therefore the authors decided to address the issues of multiple complications in the process of DDH treatment. Many authors emphasize occurrence of complications in the process of DDH treatment.<sup>17-19</sup> During conservative treatment Pavlik harness, “Koszli” harness or splints are considered hazardous as their usage may lead to ischemia of head of femur leading to its necrosis or reversible palsy of femoral nerve.<sup>20</sup> In turn, the dislocation of head of fe-

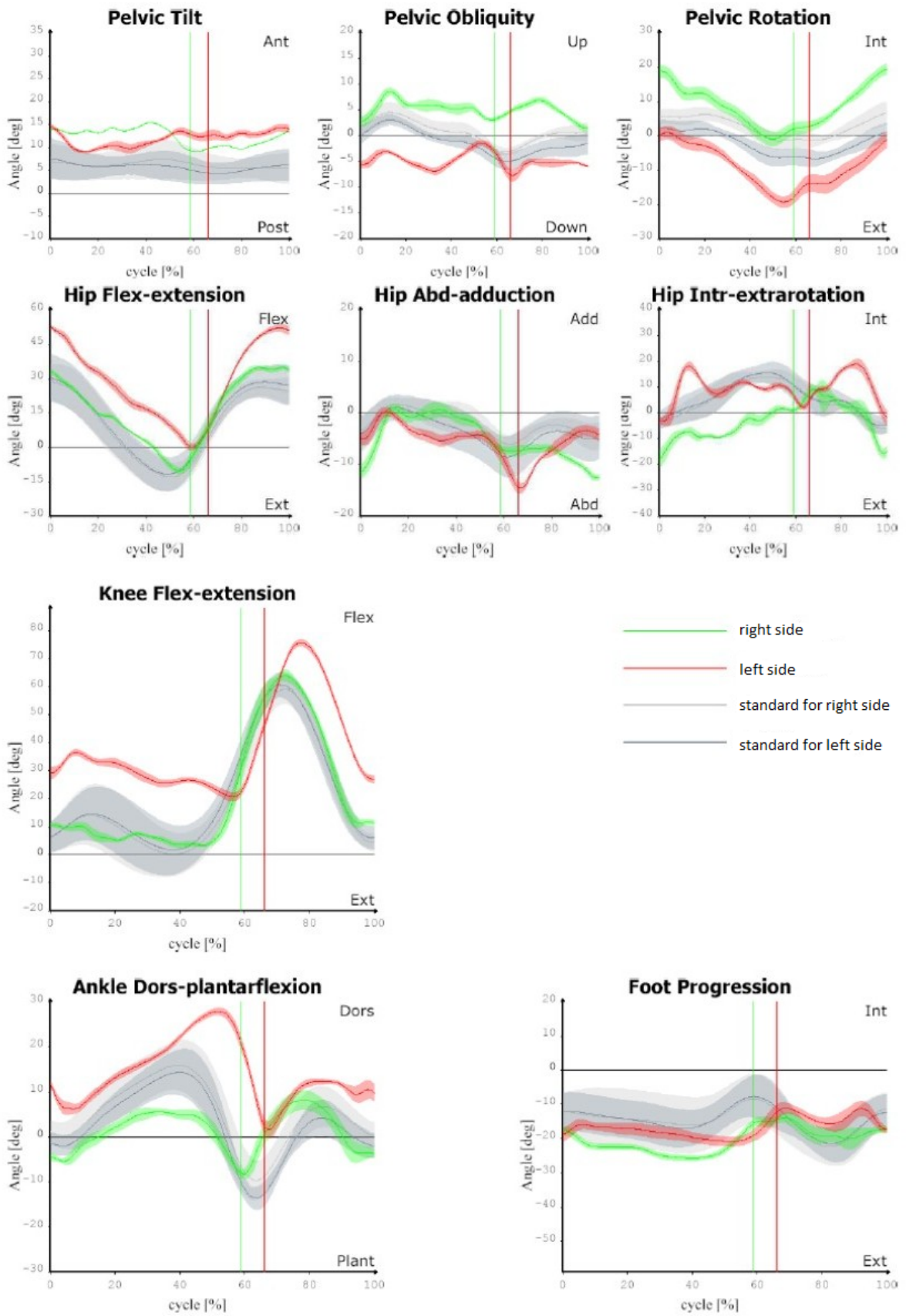


Fig. 5. Kinematic gait parameters

mur and pelvis, joint stiffness, necrosis of head of femur or subsequent joint dislocation can become post-surgical complications. Another possible complication includes dysmorphia of the head of femur, its necrosis or weakening of hip joint muscle strength as observed in our patient.<sup>20</sup> In this case study, in spite of early diagnosis and undertaken treatment the complications such as dislocation of femoral head, incorrect development of acetabulum or delayed bone union have been occurring systematically. Many authors underline the correlation between risk factors and treatment methods and the age of patient when luxation or DDH was diagnosed.<sup>17-20</sup> Our patient initially was treated conservatively, but ineffectiveness of surgical methods imposed open reposition. This surgery was repeated over the years with additional osteotomies. Wenger et al. suggest the application of conservative methods in small patients while in older children they recommend implementation of surgical methods including osteotomy.<sup>9</sup> Those surgical methods focus on recreation of proper bio-mechanics of joint and are very crucial for further prognosis. Osteotomy within femur and/or pelvis should minimize the risk of dislocation and necrosis. The authors propose to decrease the number of surgical procedures on bones as they negatively influence circumarticular soft tissue.<sup>9,21</sup>

Such an option did not concern our patient due to constant, ineffective treatment results. Recurring dislocation of head of femur imposed the utilization of open methods. Ahamed Sami Barakat et al. in the research stated that in a part of 20 patients with DDH treated with closed reposition method with tenotomy of adductors there was the necessity to perform the next procedure with the use of open reposition.<sup>21</sup> Naeem ur Razaq M et al. diagnosed the necrosis of femoral head in 8,3% patients treated with open reposition with osteotomy. Moreover, 5 % of patients showed residual dysplasia of hip joint and subsequent luxation and 3,3% of patient suffered from joint infection.<sup>22</sup> By analyzing literature and treatment history of our patient, above mentioned complications cannot be excluded, but due to lack of sufficient diagnostics they cannot be confirmed. Open reposition of luxated hip joint is considered risk factor of femoral head necrosis<sup>23-24</sup> Barakat et al. noted several cases of necrosis of the head of femur after aggressive joint manipulation. Their research shows that tenotomy does not prevent the necrosis.<sup>21</sup> Schur et al. obtained opposite results. The analyses of treatment results of 82 patients with closed reposition done in operating theatre did not produce significant difference in occurrence of necrosis of the head of femur (AVN).<sup>25</sup> It also concerned the cases with previous use of Pavlik harness, joint traction or tenotomy of adductors. They stated, however, that in male patients treated with closed reposition, secondary AVN may occur more frequently. The research conducted by Mulpuri K et al. showed that in DDH patients

diagnosed between 6 -18 months, hip dislocation was more frequent than in patients diagnosed before 3 month of life.<sup>26</sup> Our patient suffered from joint decentralization, although she was diagnosed with DDH in the second month of her life. Both, initial treatment with extension and closed reposition failed. Roposch underlines negative influence of necrosis on formation of joint surface regardless the treatment method. He states that swift improvement of function concerns joints without AVN.<sup>27</sup> Kothari analyzed the treatment results of patients treated by open method or without osteotomy. Based on evaluation of radiological effects, clinical examinations and percentage of complications (AVN) he stated that open reposition with osteotomy should be considered one of the most appropriate treatment methods, ensuring durable results.<sup>28</sup> Analyses of the literature leads to the conclusion that complication in DDH treatment are not rare in spite of properly conducted treatment.<sup>29</sup> Therapy and desired functional results are complicated due to secondary effects such as uneven length of lower limbs, persistent luxation of head of femur or incorrect joint structure.<sup>30</sup> In the presented case, drawing the conclusion about the reasons of occurring complications is quite difficult due to lack of sufficient diagnostics. Orthopedic treatment was completed and patient has been undergoing physiotherapy due to functional deficits. The deficits and dysfunctions in her motor organ include trunk asymmetry, features of scoliosis, gait pattern disorders, gait with help of elbow crutches, difference in length of lower limbs, weakening of muscle strength and ROM of joints of right lower limb.

To assess the results of two years long physiotherapy process and long orthopedic treatment, the gait analyses was performed. Gahramanov et al. performed similar analyses in patients after the osteotomy of hip joint. The authors claim that gait pattern of patients treated with osteotomy is partly similar to the gait pattern of healthy people; however it still cannot be considered a proper one. The functional effects of surgeries frequently differ from theoretical assumptions.<sup>30</sup> Gait analyses performed by authors indicate severe disorders.

Based on obtained results of both clinical examination and gait analyses it seems essential to include physiotherapy procedures into orthopedic treatment. Such an approach assures complexity of the treatment and improves life quality of DDH patients. The physiotherapy procedures performed on patient included: gait reeducation (with or without orthopedic appliances), proprioception and balance improvement, PNF posture correction, application of Kaltenborn – Evjenth manual therapy on soft tissue and fascia to improve the (slide in the joint), range of movement and contracture reduction. In the next stage, the obtained effects were used in functional therapy aimed at the patient's goals (riding a bicycle, scooter, walking without elbow crutches).

## Conclusion

1. Despite an early diagnosis and treatment of hip luxation in DDH, surgical treatment does not always bring anticipated results and can cause unwanted compensations in motor organ.
2. Obtained improvement seen in both clinical examination and gait analyses confirms the grounds for conjunction between individual physiotherapy and orthopedic treatment. This unified process should be initiated as early as possible, preferably on the day of DDH diagnosis, what will enable to avoid many complications such as wrong gait patterns, wrong trunk compensations, risk of scoliosis and reoccurrence of joint destabilization in further treatment and recovery process. In the next stage, the obtained effects were used in functional therapy aimed at the patient's goals (riding a bicycle, scooter, walking without elbow crutches).

## References

1. Pietrzak Sz, Czubak J. Jak się wykonuje badanie przesiewowe stawów biodrowych u noworodków i niemowląt. *Pediatr Dypl.* 2012;16(6):42-45.
2. Maciałczyk – Paprocka K. Epidemiologia wad postawy u dzieci i młodzieży. Praca doktorska. Poznań 2013 r. Uniwersytet Medyczny im. Karola Marcinkowskiego w Poznaniu.
3. de Hundt M, Vlemmix F, Bais JM, et al. Risk factors for developmental dysplasia of the hip: a meta-analysis. *Eur J Obstet Gynecol Reprod Biol.* 2012;165(1):8-17.
4. Randall T, Loder, Elaine N, Skopelja. The Epidemiology and Demographics of Hip Dysplasia. *International Scholarly Research Network ISRN Orthopedics.* 2011; 238607,46 pages. doi:10.5402/2011/238607
5. Noordin S, Umer M, Hafeez K, Nawaz H. Developmental dysplasia of the hip. *Orthop Rev.* 2010;2(2):73-78.
6. Clarke NM. Developmental dysplasia of the hip: diagnosis and management to 18 months. *Instr Course Lect.* 2014;63:307-311.
7. Razaq MN, Younas M, Awan AS, Waqas, Alam MI. Risk factors leading to developmental complications after open reduction In developmental dysplasia of the hip. *J Ayub Med. Coll Abbottabad.* 2016;28(1):26-28.
8. Storer SK, Skaggs DL. Developmental dysplasia of the hip. *Am Fam Physician.* 2006; 15;74(8):1310-1316.
9. Wenger DR. Surgical treatment of developmental dysplasia of the hip. *Instr Course Lect.* 2014;63:313-323.
10. Sewell MD, Rosendahl K, Eastwood DM. Developmental dysplasia of the hip. *BMJ.* 2009;24:339:b4454
11. Laborie LB, Engesæter IØ, Lehmann TG, Eastwood DM, Engesæter LB, Rosendahl K. Screening strategies for hip dysplasia: long-term outcome of a randomized controlled trial. *Pediatrics.* 2013;132(3):492-501.
12. Choudry Q, Goyal R, Paton RW. Is limitation of hip abduction a useful clinical sign in the diagnosis of developmental dysplasia of the hip? *Arch Dis Child.* 2013;98(11):862-866.
13. Dezateux C, Rosendahl K. Developmental dysplasia of the hip. *Lancet.* 2007;369 (9572):1541-1552.
14. Shorter D, Hong T, Osborn DA. Cochrane Review: Screening programmes for developmental dysplasia of the hip in newborn infants. *Evid Based Child Health.* 2013;8(1):11-54.
15. Holman J, Carroll KL, Murray KA, Macleod LM, Roach JW. Long-term follow-up of open reduction surgery for developmental dislocation of the hip. *J Pediatr Orthop.* 2012;32(2):121-124.
16. Waško MK, Pietrzak S, Szarejko A, Przybysz W, Parol T, Czubak J. Wyniki radiologiczne leczenia rozwojowej dysplazji stawów biodrowych wyciągiem ponad głowę u dzieci niechodzących. *Ortop Traumatol Rehabil.* 2017;19(2):127-136.
17. Tsukagoshi Y, Kamegaya M, Kamada H, et al. The correlation between Salter's criteria for avascular necrosis of the femoral head and Kalamchi's prognostic classification following the treatment of developmental dysplasia of the hip. *Bone Joint J.* 2017;99-B(8):1115-1120.
18. Eastwood DM, de Gheldere A. Clinical examination for developmental dysplasia of the hip in neonates: how to stay out of trouble. *BMJ.* 2010;340:c1965.
19. Sankar WN, Young CR, Lin AG, Crow SA, Baldwin KD, Moseley CF. Risk factors for failure after open reduction for DDH: a matched cohort analysis. *J Pediatric Orthop.* 211;31(3):232-239.
20. Sionek A, Czubak J, Kornacka M, Grabowski B. Określenie czynników ryzyka rozwojowej dysplazji stawów biodrowych u dzieci urodzonych z ciąż wielopłodowych. Ocena w badaniu ultrasonograficznym z zastosowaniem metody Grafa. *Ortop Traumatol Rehabil.* 2008;10(2):115-130.
21. Barakat AS, Zein AB, Arafa AS, et al. Closed reduction with or without adductor tenotomy for developmental dysplasia of the hip presenting at walking age. *Curr Orthop Pract.* 2017;28(2):195-199.
22. Naeem ur Razaq M, Risk factors leading to developmental complications after open reduction In developmental dysplasia of the hip. *J Ayub Med Coll Abbottabad.* 2016;28(1):26-28.
23. Roposch A, Protopapa E, Cortina-Borja M. Weighted diagnostic criteria for developmental dysplasia of the hip. *J Pediatr.* 2014;165(6):1236-1240.
24. Carrera N, Colmonero E, Castelo JL, Guisan A, Naviera E, Lorenzo JR. Risk of developmental dysplasia of the hip in patients subjected to the external cephalic version. *An Pediat (Barc).* 2018;88(3):136-139.
25. Schur MD, Lee C, Arkade A, Catalano A, Choi PD. Risk factors for avascular necrosis after closed reduction for developmental dysplasia of the hip. *J Child Orthop.* 2016;10:185-192.
26. Mulpuri K, Schaeffer EK, Andrade J, et al. What risk factors and characteristics are associated with late-presenting dislocations of the hip in infants? *Clin Orthop Relat Res.* 2016;474(5):1131-1137.

27. Roposch A, Ridout D, Protopapa E, Nicolaou N, Gelfer Y. Osteonecrosis complicating developmental dysplasia of the hip compromises subsequent acetabular remodeling. *Clin Orthop Relat Res.* 2013;471(7):2318-2326.
28. Kothari M, Grammatopoulos G, Hopewell S, Theologis T. How does bony surgery affect results of anterior open reduction in walking-age children with developmental hip dysplasia? *Clin Orthop Relat Res.* 2016;474(5):1199-1208.
29. Farsetti P, R. CateriniR, Potenza V, Ippolito E. Developmental dislocation of the hip successfully treated by pre-operative traction and medial open reduction: A 22-year mean followup. *Clin Orthop Relat Res.* 2015;473(8):2658-2669.
30. Gahramanov A, Inanici F, Caglar O. Functional results in periacetabular osteotomy: is it possible to obtain a normal gait after the surgery? *Hip Int.* 2017;27(5):449-454.