





## CASUISTIC PAPER

Katarzyna Ustarbowska <sup>1(ABCDG)</sup>, Bartosz Trybulec <sup>2(ADFG)</sup>

# Physiotherapeutic management of a patient with patellofemoral pain syndrome – a case report

<sup>1</sup> Student of master's degree studies on Physiotherapy, Faculty of Health Sciences, Jagiellonian University Medical College, Poland

<sup>2</sup> Department of Physiotherapy, Faculty of Health Sciences, Jagiellonian University Medical College, Poland

## ABSTRACT

**Introduction.** Patellofemoral pain syndrome (PFPS) is a disorder of the front compartment of the knee joint with incompletely investigated, probably multifactorial pathogenesis. It mostly affects young people and runners. In patients with PFPS conservative management is a therapy of choice with fundamental importance of physiotherapeutic procedures. Therapy should be highly individualized and considering all possible factors that may cause PFPS symptoms.

**Aim.** The aim of this report was presentation of management of a 23 year old female patient with PFPS that developed secondary to a knee sprain. The medical history, diagnostic and therapeutic procedures were thoroughly described, then obtained results were presented and thereafter discussed.

**Methods.** Clinical assessment included functional and provocative tests of the patellofemoral joint as well as thigh and calf muscles tests, range of motion measurement of the knee joint and pain assessment using the VAS scale. Therapeutic management included 5 sessions of post-isometric muscle relaxation (PIR), mobilizations of the patella and applications of elastic tapes.

**Results.** After 5 sessions of therapeutic management PFPS symptoms were significantly reduced. Pain did not occur during normal activity, whereas in heavy joint loading, it occurred later and was of lower intensity. Range of motion as well as subjective sense of joint stability was also improved.

**Conclusions.** Individually adjusted conservative management based on PIR techniques, mobilizations of patella and kinesiotaping seems to be effective form of therapy for PFPS of functional nature.

**Keywords.** patellofemoral pain syndrome, excessive lateral pressure syndrome, runner's knee, physiotherapy, kinesiotaping

## Introduction

Patellofemoral pain syndrome (PFPS) also called excessive lateral pressure syndrome (ELPS) is a disorder of the front compartment of the knee joint with incompletely investigated, probably multifactorial patho-

genesis. It mostly affects young, active people while in women it appears twice often than in men. Also, due to frequent appearance in persons practicing running, the term “runner's knee” is commonly used with reference to this syndrome.<sup>1,2</sup>

**Corresponding author:** Bartosz Trybulec, e-mail: bartosz.trybulec@uj.edu.pl

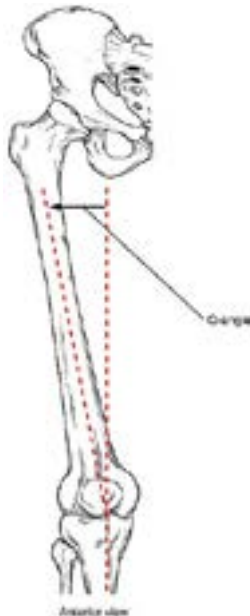
**Participation of co-authors:** A – Author of the concept and objectives of paper; B – collection of data; C – implementation of research; D – elaborate, analysis and interpretation of data; E – statistical analysis; F – preparation of a manuscript; G – working out the literature; H – obtaining funds

Received: 12.12.2017 | Accepted: 02.03.2018

Publication date: March 2018

PFPS together with habitual subluxation of patella and its recurrent dislocation sets a group of disorders with one characteristic feature - patellofemoral malalignment. PFPS is highlighted in this group only with chondromalacia which is always present in PFPS while it is not regular in both others.<sup>2</sup> PFPS may occur as patellofemoral instability, pain that can be assisted with patellofemoral malalignment or isolated pain.<sup>1</sup>

External risk factors of PFPS include patellofemoral joint overloading i.e. training errors (accumulation of micro-trauma), sudden increase of training intensity or frequency, improper footwear and also knee joint traumas/surgery which may lead to damage of cartilage and/or change in distribution of forces in patellofemoral joint. Internal risk factors of PFPS involve various changes of knee joint structures (e.g. trochlear dysplasia, asymmetry of patellar joint surfaces, hypertrophy of infrapatellar fat pad), changes of lower limb mechanical axis (e.g. patella alta, valgus knee, foot hyperpronation) and soft tissues imbalance (e.g. contracture of quadriceps m., calf muscles, iliotibial band or hamstrings, also impairment of lateral retinaculum of patella)<sup>1,3</sup>



**Figure 1.** Q-angle

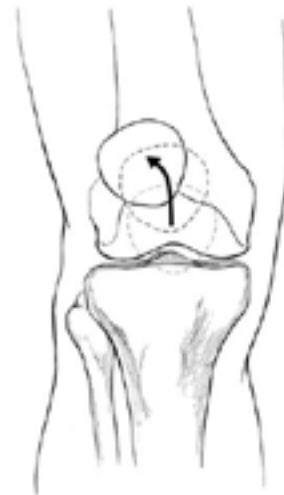(source: [https://commons.wikimedia.org/wiki/File:818\\_Femur\\_Q\\_Angle.jpg](https://commons.wikimedia.org/wiki/File:818_Femur_Q_Angle.jpg))

Primary symptoms of PFPS are often non-specific with a tendency to be ignored by patients. The onset can be acute or chronic and typical symptoms are: uni- or bilateral dull pain located under or around the patella, knee stiffness and clicking/cracking or crepitus inside the joint.<sup>1,2</sup> The characteristic feature of PFPS is increase of pain during long time maintained knee flexion (“theater sign”) and also during activities forcing the joint e.g. climbing/descending the stairs, running, squatting,

kneeling etc. Nocturnal pain can also occur in case of sleeping with flexed knees. Secondary PFPS symptoms can be subjective knee instability (weakness of quadriceps m.). Complete blockage of knee joint is not specific for PFPS and require differentiation with meniscus damage or presence of loose articular bodies.<sup>1,2</sup>

The diagnosis of PFPS is mainly based on assessment of present and former clinical symptoms. Specific examination that assess deviation of the patella from lower limb axis is measurement of Q-angle which is set between the line connecting front upper iliac spine with the center of patella and line connecting center of patella with front tibial tuberosity (Fig.1.). The value of Q-angle over  $16^\circ$  indicates the increase of force that pulls the patella laterally.<sup>1,4</sup>

Another specific examination for patellofemoral malalignment is so called “J-sign” that characterizes the trajectory of movement of the patella which is pulled laterally at the end of extension by excessively tensed lateral stabilizers (Fig.2).<sup>2</sup>



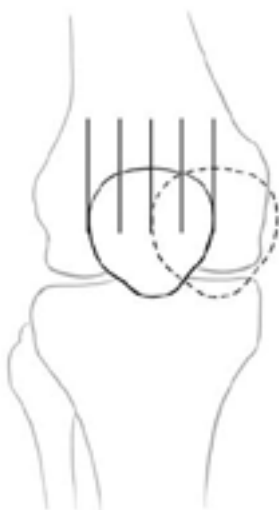
**Figure 2.** “J-sign”<sup>2</sup>

The presence of chondromalacia can be assessed by joint surface pressure test in lying position, patella moving test and by checking the influence of quadriceps m. on pain in the patellofemoral joint (Zohlen sign). Medial patella glide should also be examined as it may show shortening of lateral retinaculum – the result is positive if examiner cannot move the patella medially by about a half of its width (Fig.3).<sup>2</sup>

The comprehensive diagnostics of PFPS should consider other aspects that could determine its occurrence e.g. elasticity of m. quadriceps and assessment of iliotibial band, hamstrings and calf muscles length since their shortening may increase pressure of the patella to femur by permanent initiation of flexed position.<sup>1,2,5</sup>

Additional imaging (X-ray, MRI) are secondary to functional assessment in diagnostic of PFPS because

positive results of these examinations neither determine the presence of this disorder nor the risk of its occurrence in future. They are applicable in excluding other possible causes of patellofemoral pain, especially in patients with trauma in medical history.<sup>1,2</sup>



**Figure 3.** Patella glide test<sup>2</sup>

Because PFPS is most often of functional nature thus the therapy of choice is individualized comprehension management that consider all structural and biomechanical dysfunctions. It provides mainly stretching of shortened structures (mostly iliotibial band, quadriceps muscle, hamstrings and calf muscles) and strengthening of weakened groups of muscles (extensors and rotators of the hip joint).<sup>7</sup> The core stability, sensomotoric and proprioceptive exercises on unstable basis and correction of postural faults should also be considered. The manual therapy techniques are likely to be used for restoring of correct mobility of the patellofemoral joint.<sup>1,2</sup> The correction of the patella position can also be achieved by using Kinesiotaping applications. Secondary prevention should include reduction of patellofemoral joint loading, for example, by changing the type of previous activity for that generates smaller joint compression (e.g. riding the bike cycloergometers, swimming), using proper training footwear or reduction of body mass.<sup>1,3,7</sup>

The surgery (i.a. lateral retinaculum release, reconstruction of medial retinaculum, patella chondroplastics) is introduced in case of lack of conservative treatment effects. It should be considered for those patients who didn't improve after conservative treatment that lasted a minimum of 6 months and other possible causes of PFPS excluded.<sup>2</sup>

The aim of this report was the presentation of physiotherapeutic management of young female patient with PFPS that developed secondary to a knee sprain.

### Case report

The patient is a 23 year old accountant leading moderately active lifestyle – hiking in her spare time and occasionally dancing and participating in group fitness activities.

The original trauma occurred during physical education class. A knee joint sprain was diagnosed in a hospital emergency room on the basis of an x-ray picture. After the fitting of plaster cast, the patient was discharged with a recommendation of a complete unloading of the injured leg. The cast was removed after three weeks and patient was advised to progressively return back to normal function with continuous assistance of crutches. The patient regained the ability to perform normal daily activities without knee pain in about 4 months after trauma.

About 7 months after the original trauma during physical education class symptoms returned. After orthopedic consultation, ultrasound imaging revealed changes in the patellofemoral joint described as chondromalacia of first grade. Simultaneously, damage of other joint structures was excluded. The patient was administered to 10 sessions of laser and local cryotherapy and was advised for taking supplementation of glucosamine sulfate, hyaluronic acid and collagen which diminished the symptoms for short time with subsequent recurrence with variable intensity until present time.

### Functional diagnostics.

The patient sought physiotherapeutic consultation about 7 years after the original trauma due to recurrent ailments of the right knee. The symptoms were described as a feeling of crushing and pressuring inside the joint mostly localized medially nearby lower part of the patella and on the level of the joint fissure. Pain was intensified by long term flexion or excessive loading of the knee joint and was of dull and continuous character depending on the patient's activity level. Its intensity at rest was evaluated as low (0-2 in VAS scale) but was aggravating during climbing stairs, long walking or hiking (5-8 in VAS scale). Sometimes pain was accompanied by a feeling of clicking or friction inside the joint, especially in maximal knee flexion. An evident lateral shift of the patella without features of valgus or varus knee was found visually. The affected right knee joint was found to be 1 cm larger in circumference by comparative measurement. The medial part of right knee joint fissure was also found touch-sensitive. The results of functional tests and range of motion (ROM) measurement clearly stated contracture of quadriceps and gastrocnemius muscles. Lateral patella subluxation with shortening of lateral retinaculum was also noticed. Performance of McConnell test evaluating the influence of patella medialization on knee pain was impossible because of large lateral pressure in patellofemoral joint.

**Table 1.** Details of the patient's functional assessment

Test/Examination	Result	Interpretation
Dancing patella	positive	effusion in right knee joint
Facet tenderness	positive	damage/degenerative changes of right patella cartilage
Zohlen's sign	positive	
Patella moving test	positive	
Crepitation test	positive	patellofemoral joint chondromalacia
"J-sign" (R/L)	positive /negative	increased forces pressuring right patella laterally
Q angle (R/L)	21°/17°	
Lateral Subluxation Suppression Test	positive	lateral subluxation of right patella
Ober Test	negative	no iliotibial band shortening
Patella Glide test	limitation of medial glide	shortening of lateral retinaculum
Thomas Test (R/L)	positive /negative	contracture of right rectus femoris muscle
Drawer test posterior/anterior	negative/negative	efficient cruciate ligaments
Apley Distraction/Compression Test	negative	undamaged menisci
Chaitow's Discriminatory Test for gastrocnemius m. (Fig.4)	positive	gastrocnemius muscle contracture
Knee flexion ROM (active/passive)	R 117°/120° L 128°/131°	limitation of right knee joint extension
Sagittal plane ROM of ankle joints (active/passive)	R 40-0-15°/47-0-22° L 45-0-18°/45-0-30°	minor limitation of right ankle joint mobility

captions: R – right, L – left

All dysfunctions revealed in functional assessment presented a range of symptoms typical for PFPS of functional character (Table 1).

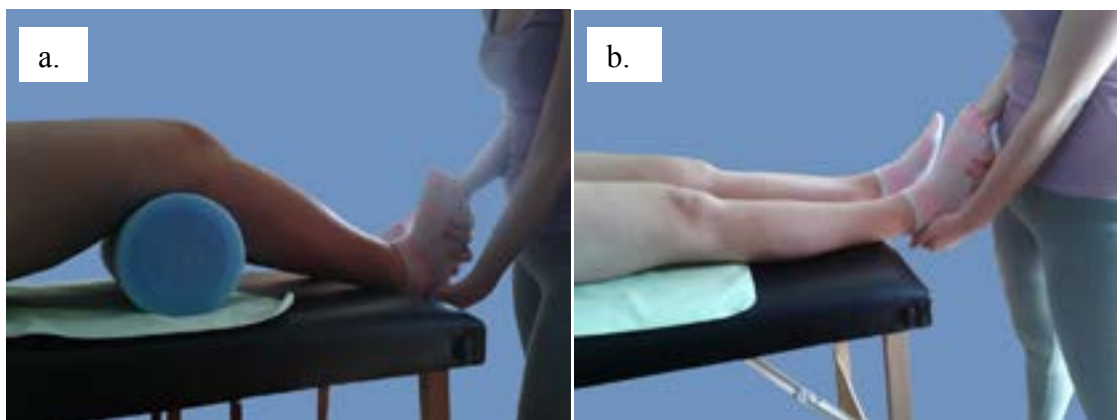
**Physiotherapeutic management**

The goal of the therapy was reduction of exertional knee pain to the extent that allows covering moderate mountain hikes and elimination of pain occurring during daily activities. There were 5 physiotherapeutic sessions performed daily or in a maximal 3 day interval which lasted on average 35-45 minutes. Each one session included Swedish massage of whole right lower

limb, and post-isometric muscle relaxation techniques (PIR) described by Chaitow on quadriceps and gastrocnemius muscles.<sup>5</sup> Following this, patella mobilizations and Kinesiotaping applications were performed. After the last session complete functional diagnostics were repeated.

**Post-isometric relaxation techniques (PIR)**

In order to prepare the muscles for PIR, each session was started with Swedish massage of whole right lower limb. Then the PIR technique for gastrocnemius muscle was performed. The patient was lying supine on a



**Figure 4.** Chaitow's Discriminatory Test for gastrocnemius m.: a. correct elasticity of soleus m., b. contracture of gastrocnemius m. (own material)

therapeutic table. Her lower limbs were straightened with feet off the table. One of the therapist's hands supports the heel grasp Achilles tendon and the other was placed on foot dorsally with the thumb medially on the plantar side. With passive movement as used in stretching, the therapist found the limit of dorsiflexion and positioned the foot just before this limit with muscle partly relaxed (Fig.5a.). The patient was then asked for isometric plantar flexion against a constant resistance of 25-30% of maximal force applied by the therapist for 7 seconds. After muscle relaxation and 5 seconds of rest, the foot was positioned in maximal painless dorsiflexion within the new ROM limit and held for a minimum of 30 seconds (Fig.5b.). To increase the effectiveness of this technique, a special breathing cycle was introduced that consisted of breathing in during isometric contraction increase, and holding breath during maximal contraction. Then during rest before muscle stretching, a long breathing out was performed in order to facilitate full relaxation.

Subsequently, the same technique was used for the rectus femoris muscle. The patient was lying prone with right knee bent. The therapist was supporting the leg

with one hand on the level of ankle joint and stabilizing the pelvis with other hand on the sacrum (Fig. 6a.). Then the patient was asked to perform isometric knee extension against constant resistance applied by the therapist with simultaneous attempt of hip flexion by pushing the thigh against the table. The contraction was maintained for 7 seconds and involved about 25-30% of the patient's maximal power. After relaxation and rest that lasted up to 5 seconds, the shin was positioned in maximal painless knee flexion and held for at least 30 seconds (Fig. 6b.). The special breathing cycle described above was also adopted in this procedure.

Each session provided three repeats of the complete sequence separately for both muscles while each repeat was started just before a new ROM limit.

### Patella mobilizations

To restore correct elasticity of lateral retinaculum, a passive medial mobilization of the patella of second degree by Maitland was used.<sup>8</sup> The second degree of mobilization was explained by pain occurring before first resistance during glide. The patient was lying supine with both legs straightened. The therapist held the patella

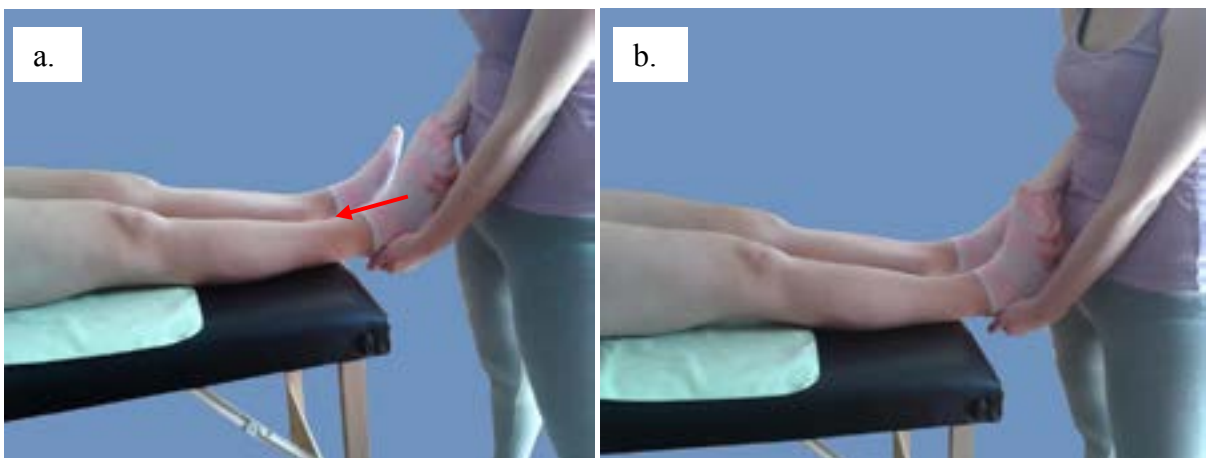


Figure 5. PIR for gastrocnemius muscle: a. Starting position, b. Final position (own material)

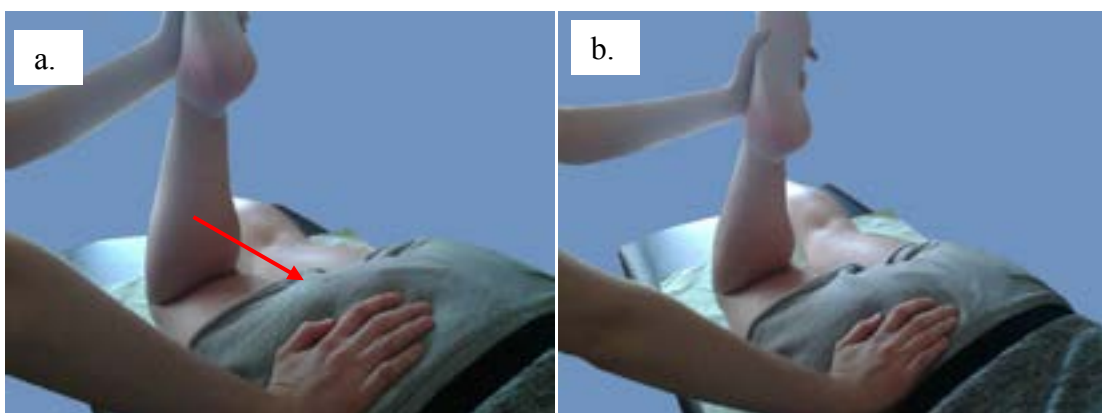


Figure 6. PIR for rectus femoris muscle: a. Starting position, b. Final position (own material)



with thumbs along the lateral margin with forefingers on the opposite side (Fig.7a.). Afterwards, the patella was moved medially up to the movement limit without any pain (Fig.7b.). Patella was held in this position for 15 seconds and then moved back to the starting position. This procedure was repeated 5 times with several seconds intervals.

### Kinesiotaping

In order to maintain the therapeutic effects obtained being the stretching of lateral retinaculum and unloading of lateral femur condyle, the correction of patella alignment by elastic tapes application was used. The application applied was of mechanical correction type in which positional stimulus induces required resting position. It enables the maintenance of a full and functional ROM, simultaneously inhibiting pathological compensation patterns. In the patient described, this application was

assumed to limit excessive lateral glide observed mainly at the end of knee extension.

The patient was lying supine with both knees bent. Three parts of tape each 15 cm long were prepared. First “I” shaped and 5 cm wide tape was applied arch-like to hold the patella from its lateral side and pushing medially. During tape application the patient was asked for active knee flexion while the medial 1/3 part of tape was applied with 50% tension along the lateral margin of the patella. In maximal knee flexion, both bases of tape were stuck without tension (Fig.8a.). Afterwards in the same position of the patient, both “V” shaped parts of tape were applied with bases put without tension one below the other on the medial side of the knee joint. Application was performed in knee flexion, sticking particular parts of tape so as they grasp the patella between them. The tension of tape was 30% while all ends were stuck without any tension (Fig.8b).

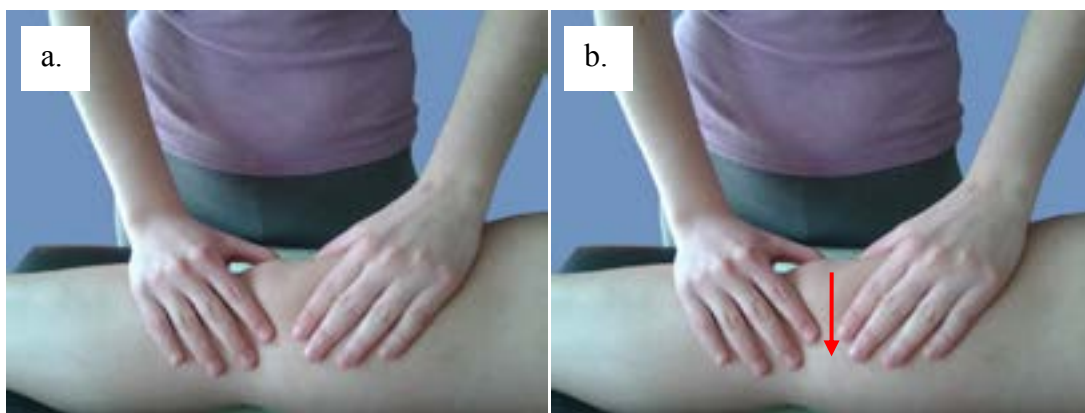


Figure 7. Medial patella mobilization by Maitland: a. Starting position, b. Final position (own material)

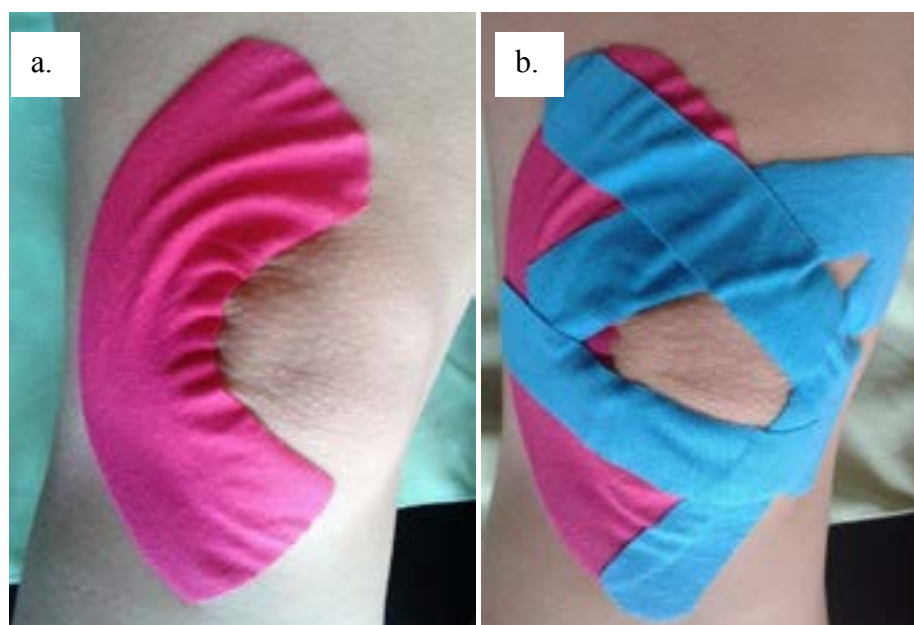


Figure 8. Kinesiotaping of patellofemoral joint: a. Basic mechanical correction, b. Full application correcting lateral dislocation of the patella (own material)

## Results

Before therapy, the patient evaluated pain intensity of 2 at rest and an increase up to 3 on the VAS scale during stair climbing. Pain reduction was observed during the first therapeutic session while analgesic effects were increased and became stable after each session. As a final result, complete pain elimination during daily activities was achieved. Maximal pain intensity in heavy joint loading e.g. during long hiking times was evaluated as 2 on the VAS scale, moreover, symptoms occurred markedly later than before therapy. Clicking and cracking inside the joint occurred less often and became painless. Facet tenderness and patella moving tests were found negative. Pain during the Zohlen test was also diminished. The patient subjectively noticed a greater freedom of movement and stability during walking. Angular measurements showed significant improvement of ROM in the knee and ankle joint. Right knee flexion came to 130°, foot plantar flexion to 45°, and foot dorsiflexion to 20° and these values were comparable with those in left leg. Complete functional assessment was repeated 6 weeks later and the results were the same as just after the end of therapy.

## Discussion

In this report we presented patellofemoral pain syndrome and an example of physiotherapeutic management in a patient with this disorder that developed as a late complication after a knee sprain. This program may be also applied in other patients in which limitation of ROM in the knee joint or patellofemoral joint occurred on the basis of muscle imbalance. The use of therapy that combines various interventions depending on individual factors determining PFPS occurrence is considered as an effective and recommended form of treatment.<sup>1,2,3</sup> One of the elements included in the presented management was Kinesiotaping (KT) of which effectiveness in PFPS was stated i.a. by Campolo et al. who compared two different methods of taping in group of 20 persons with unilateral PFPS. They reported significantly larger improvements in pain during stair climbing and getting up out of a squat position in a group with KT than in a control group without taping.<sup>9</sup> Chen et al. examining EMG of vastus medialis and vastus lateralis muscles in patients with PFPS noticed normalization of activation of both muscles after KT in comparison to placebo which directly corrected patella alignment and reduced pain.<sup>10</sup> In contrast, Kuru et al. comparing the effect of KT and electrostimulation combined with identical exercise programs ascertained the same level of improvement of both interventions.<sup>11</sup> Akbas et al. compared two groups of women who underwent therapeutic programs including exercises and muscle stretching with additional KT applied every 4 days in one group. The authors stated no significant

differences between both groups in mobility and pain, however, in the KT group a faster improvement in hamstring elasticity was noticed.<sup>12</sup> These findings, regardless of differences, encourage us to consider Kinesiotaping as an effective method of mechanical correction of patella alignment that can be included in a comprehensive management of patients with PFPS.

Relatively little information has been issued about the use of manual therapy (MT) in therapy of PFPS. In the presented case, a glide mobilization described by Maitland was used of which effectiveness in the treatment of degenerative disease of the patellofemoral joint was confirmed by Kumar.<sup>13</sup> Van den Dolder et al. reported improvement in knee flexion after mobilization with movement in sagittal plane combined with deep friction massage.<sup>14</sup> Espi-Lopez et al. conducted a systematic review of reports about the use of MT combined with other physical modalities in PFPS treatment. The authors in appraising the results of 5 randomized clinical trials confirmed the effectiveness of MT in management of PFPS mainly in combination with muscle strengthening and stretching. They perceived, however, that better therapeutic effects can be expected after combination of these techniques is applied on both hip and knee joints than acting on knee joints only.<sup>15</sup>

In the presented case, the use of post-isometric relaxation techniques was motivated by the presence of rectus femoris and gastrocnemius muscle contracture of which relationship to PFPS was stated by Waryasz and McDermott.<sup>16</sup> High effectiveness of quadriceps stretching in PFPS treatment was stated before by i.a. Mason et al. who compared efficacy of stretching with muscle strengthening and taping. They noticed significant improvement in function and pain just after a one week session of muscle stretching.<sup>17</sup> In turn, Moyano et al. comparing classic stretching exercises with PNF stretching techniques (hold-relax), observed a bigger improvement in PNF group than in classic stretching group.<sup>18</sup>

Implementation of combined physiotherapeutic methods presented in this paper provided quick pain reduction and improvement of knee mobility. Persistence of these results was confirmed in clinical examination conducted 6 weeks after the end of therapy. Satisfactory outcomes of this management may hold promise for effective treatment for patients who didn't get proper physiotherapeutic assistance in the acute phase of this disorder. However, precise identification of individual functional deficits related to PFPS and, on this basis, the choice of relevant therapeutic techniques, seems to be crucial.

## Conclusions

1. Patellofemoral pain syndrome is a common disorder of the knee joint with complex and individual

etiology that causes pain and severe functional impairment of the lower limbs.

- Individually programmed conservative management based on post isometric relaxation techniques, mobilizations of patella and Kinesiotaping seems to be an effective therapy for patellofemoral pain syndrome of a functional nature.

## References

- Hryvniak D, Magrum E, Wilder R. Patellofemoral Pain Syndrome: An Update. *Curr Phys Med Rehabil Rep.* 2014;2(1):16-24.
- Dixit S, Difiori JP, Burton M, Mines B. Management of patellofemoral pain syndrome. *Am Fam Physician.* 2007;75(2):194-202.
- Petersen W, Ellermann A, Gösele-Koppenburg A, et al. Patellofemoral pain syndrome. *Knee Surg Sports Traumatol Arthrosc.* 2014;22(10):2264-2274.
- Weiss L, DeForest B, Hammond K, Schilling B, Ferreira L. Reliability of goniometry-based Q-angle. *PM&R.* 2013;5(9):763-768.
- Chaitow L. *Techniki energii mięśniowej.* Wyd. 3. Wrocław: Elsevier Urban & Partner; 2011:147-171.
- Al-Hakim W, Jaiswal PK, Khan W, Johnstone D. The non-operative treatment of anterior knee pain. *Open Orthop J.* 2012;6(1):320-326.
- Worobel M, Gniewek T, Hadała M. Trening kontroli motorycznej w bocznym przyparciu rzepki według koncepcji Kinetic Control – opis przypadku część I. Praca globalna. *Prakt Fizjoter Rehabil.* 2013;42:12-16.
- Banks K, Hengeveld E. *Terapia manualna według Maitlanda.* Wyd. I polskie. Wrocław: Elsevier Urban & Partner; 2013:589.
- Campolo M, Babu J, Dmochowska K, Scariah S, Varughese J. A comparison of two taping techniques (kinesio and mcconnell) and their effect on anterior knee pain during functional activities. *Int J Sports Phys Ther.* 2013;8(2):105-110.
- Chen P, Hong W, Lin C, Chen W. Biomechanics effects of kinesio taping for persons with patellofemoral pain syndrome during stair climbing. In *4th Kuala Lumpur International Conference on Biomedical Engineering.* Springer Berlin Heidelberg. 2008: 395-397.
- Kuru T, Yalman A, Dereli EE. Comparison of efficiency of Kinesio® taping and electrical stimulation in patients with patellofemoral pain syndrome. *Acta Orthop Traumatol Turc.* 2012;46(5):385-392.
- Akbaş E, Atay AO, Yüksel I. The effects of additional kinesio taping over exercise in the treatment of patellofemoral pain syndrome. *Acta Orthop Traumatol Turc.* 2011;45(5): 335-341.
- Kumar A, Ganesh BR. Combined effectiveness of Maitland's mobilization and patellar taping in patellofemoral osteoarthritis: A randomised clinical trial. *Indian J Physiother Occup Ther.* 2011;5(1):14-17.
- Van den Dolder PA, Roberts DL. Six sessions of manual therapy increase knee flexion and improve activity in people with anterior knee pain: a randomised controlled trial. *Aust J Physiother.* 2006;52(4):261-264.
- Espí-López GV, Arnal-Gómez A, Balasch-Bernat M, Inglés M. Effectiveness of Manual Therapy Combined With Physical Therapy in Treatment of Patellofemoral Pain Syndrome: Systematic Review. *J Chiropr Med.* 2017;16(2):139-146.
- Waryasz GR, McDermott AY. Patellofemoral pain syndrome (PFPS): a systematic review of anatomy and potential risk factors. *Dyn Med.* 2008; 7(1):9.
- Mason M, Keays SL, Newcombe, PA. The effect of taping, quadriceps strengthening and stretching prescribed separately or combined on patellofemoral pain. *Physiother Res Int.* 2011; 16(2): 109-119.
- Moyano FR, Valenza MC, Martin LM, et al. Effectiveness of different exercises and stretching physiotherapy on pain and movement in patellofemoral pain syndrome: a randomized controlled trial. *Clin Rehabil.* 2013; 27(5): 409-417.