



CASUISTIC PAPER

Furkan Parlak ¹, Busra Bahceci ², Betul Cam ¹, Ozlem Uzun ¹, Abuzer Coskun ¹

A very rare complication of frontal sinusitis: Pott's puffy tumor

¹ Emergency Medicine Clinic, Bagcilar Training and Research Hospital, Istanbul, Turkey

² Emergency Medicine Clinic, St Helens and Knowsley Hospitals NHS Trust, Prescot, United Kingdom

ABSTRACT

Introduction. Pott's puffy tumor is a very rare clinical condition characterized by subperiosteal abscess, a complication of frontal sinusitis, or as a result of head trauma.

Aim. Early diagnosis of this condition is significantly important to prevent sequelae and severe neurological complications. This phenomenon, which is generally seen in children, can rarely be encountered in adults.

Description of the case. In this report, we share a rare case of Pott's puffy tumor in an adult patient.

Conclusion. Pott's puffy tumor, a rare complication of frontal sinusitis, should be considered to prevent neurological and intracranial complications.

Keywords. emergency, headache, Pott's puffy tumor

Introduction

Pott's puffy tumor is a rare complication of sinusitis, mastoiditis, malignancy, or insect bites.¹ It's characterized by a subperiosteal abscess with associated osteomyelitis originating from the frontal sinus. In the late 18th century, Sir Percival Pott described this phenomenon as forehead trauma and early sinusitis.² Usually, it's seen in the pediatric age group, but there are few cases reported in the adult population.³ It has a high risk of intracranial complications such as meningitis or neurological symptoms like seizures if not recognized treated early. Computed tomography (CT) scan is successfully able to diagnose this condition and detect progression into intracranial complications such as meningitis and focal abscess.⁴ Plain and contrast-enhanced cranial CT scans are accepted as the most reliable investigations, but magnetic resonance imaging, technetium-99m, and gallium-67 scans are also useful. However, these may still not show intracranial involvement precisely.⁵

Aim

Early diagnosis of sinusitis is very important to prevent sequelae and severe neurological complications. Pott's puffy tumor, a rare complication of frontal sinusitis, should be considered to prevent neurological and intracranial complications.

Description of the case

A 22-year-old man presented to the emergency department with complaints of swelling on the forehead and headache for one week. On physical examination; vitals were stable, Glasgow Coma Scale was 15 (E4, V5, M6), an 8cm x 8cm fluctuant, tender, warm swelling on the forehead was palpated (Fig. 1).

The rest of the systemic examination was unremarkable. The CT scan of the patient was reported as pansinusitis, a bone defect in the anterior wall of the right frontal sinus, and there were collection areas under the skin (Fig. 2).

Full blood count, urea and electrolytes, viral markers, glucose level, C reactive protein, and kidney function

Corresponding author: Furkan Parlak, e-mail: furkanparlak.itf@gmail.com

Received: 06.05.2021 / Revised: 06.06.2021 / Accepted: 15.07.2021 / Published: 30.12.2021

Parlak F, Bahceci B, Cam B, Uzun O, Coskun A. A very rare complication of frontal sinusitis: Pott's puffy tumor. *Eur J Clin Exp Med*. 2021;19(4):330–332. doi: 10.15584/ejcem.2021.4.8.



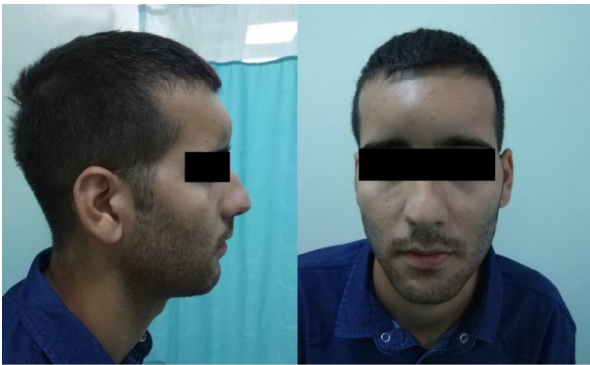

Fig. 1. An 8 cm x 8 cm fluctuant, tender, warm swelling over the forehead

tests were all within the normal range. Pott's puffy tumor was explained as a rare complication of current

clinical frontal sinusitis. The patient was referred to the otolaryngology clinic for further examination and treatment. The patient was examined by the otolaryngology clinic with a diagnostic rhinoscopy. Rhinoscopy showed bilateral hyperemic mucosa and non-obstructive turbinates. No purulent discharge was observed. The abscess was drained by an external coronal incision and the culture was taken. Empyric therapeutic 2 gr ceftriaxone was given daily by the otolaryngology clinic. The patient wanted to leave the hospital on the 2nd day of his hospitalization without waiting for the culture result. At the end of the second day, the general condition of the patient was good. The patient was started orally empiric therapeutic amoxicillin-clavulanic acid 2g/day and metronidazole 2g/day. The culture of the pus revealed *Streptococcus pneumoniae*. After 4-weeks, the patient

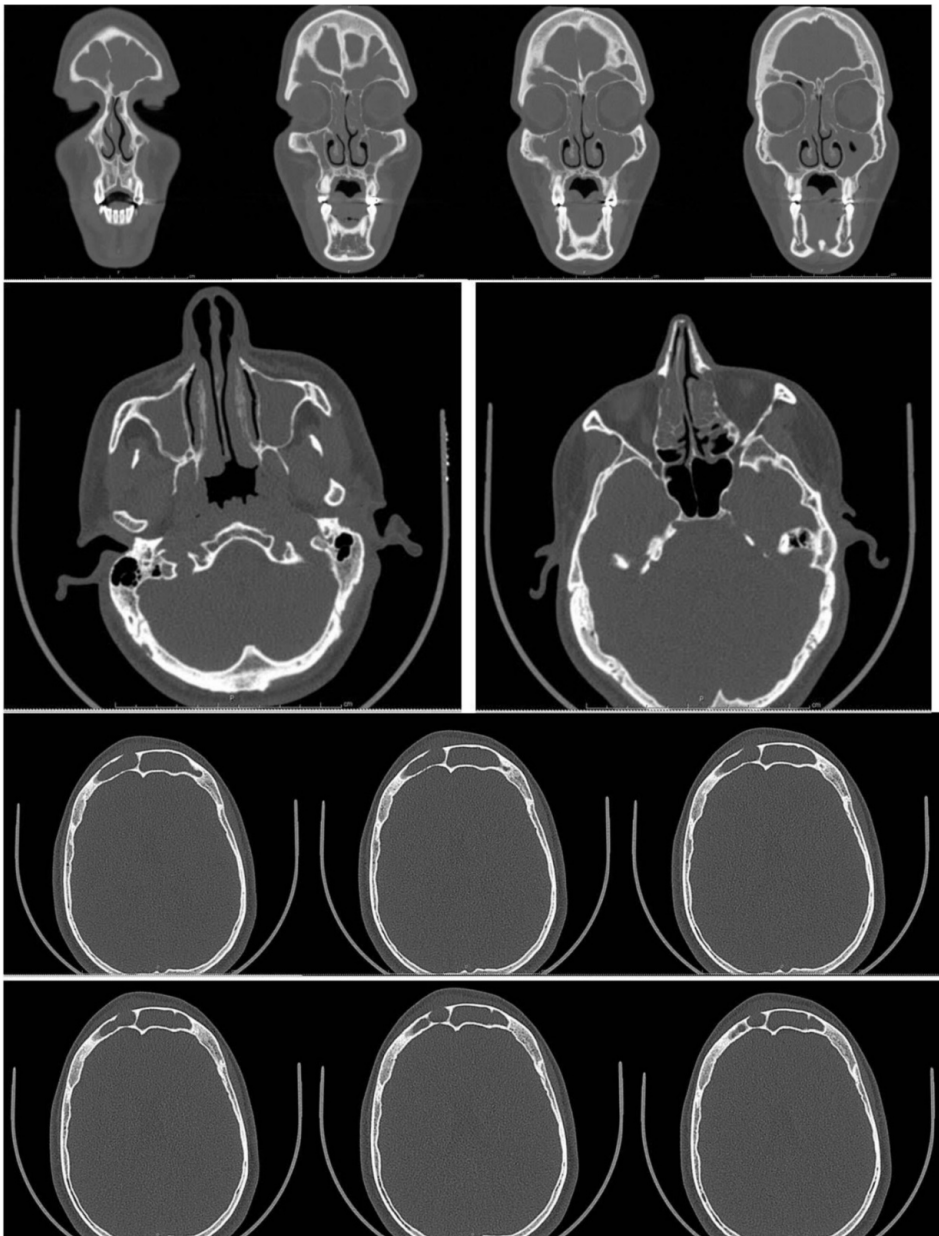


Fig. 2. Pansinusitis, bone defect in the anterior wall of the right frontal sinus, and collection are as under the skin wereseen

came for control. The patient had no complaints. Systemic examination was unremarkable. There is no need for functional endoscopic sinus surgery. The patient was treated without the need for an operation and did not suffer from neurological complications.

Discussion

Rare complications of sinusitis should also be considered in the differential diagnosis of headache, which is one of the common presentations to the emergency department.¹ Recognition of Pott's puffy tumor is very important to prevent future complications.⁶ Osteomyelitis of the frontal bone and the resulting subperiosteal abscess leads to the characteristic features of Pott's puffy tumor.⁷ The management involves surgical drainage of the abscess and commencement of the appropriate antibiotics.⁸ The most common infectious agents seen in Pott's puffy tumor are *Staphylococcus*, non-enterococcal streptococci, and anaerobes that colonize the upper respiratory tract. When this condition is not treated promptly, it can lead to neurological complications such as meningitis, epidural, or subdural abscess and neurological symptoms like seizures.⁹ Sinus surgery may be required later in untreated frontal sinusitis, as in the treatment of congenital hypoplastic sinus cases or sinusoid malignancies.^{10,11} It is vital to recognize this false tumor in the emergency department to prevent unnecessary intracranial operations, long-term antibiotic use and to reduce the length of hospital stay.¹²

Conclusion

Patients frequently apply to the emergency department with the complaint of a swelling on the forehead and associated headache. Therefore, Pott's puffy tumor, a rare complication of frontal sinusitis, should be considered to prevent neurological and intracranial complications such as abscesses, meningitis, and neurological symptoms like seizures.

Declarations

Funding

This research received no external funding.

Author contributions

Conceptualization, B.C. and F.P.; Methodology, B.C. and F.P.; Validation, O.U., A.C. and F.P.; Formal Analysis, B.B.; Investigation, B.B. and B.C.; Resources, F.P.; Data Curation, A.C.; Writing – Original Draft Preparation, F.P. and O.U.; Writing – Review & Editing, F.P., B.C. and B.B.; Visualization, F.P.; Supervision, B.C.; Project Administration, F.P.

Conflicts of interest

There is no conflicts of interest.

Data availability

This case is obtained in Bagcilar Training and Research Hospital.

Ethics approval

The informed consent was obtained from patient.

References

1. Akiyama K, Karaki M, Mori N. Evaluation of adult Pott's puffy tumor: our five cases and 27 literature cases. *Laryngoscope*. 2012; 122(11):2382-2388.
2. Bagdatoglu C, Güleriyüz A, Ersöz G, Talas DÜ, Kandemir Ö, Köksel T. A Rare Clinical Entity: Pott's Puffy Tumor. *Pediatr Neurosurg*. 2001;34:156-158.
3. Reynolds DJ, Kodosi SR, Rubin SE, Rodgers IR. Intracranial infection associated with preseptal and orbital cellulitis in the pediatric patient. *J AAPOS*. 2003;7(6):413-417.
4. Suwan PT, Mogal S, Chaudhary S. Pott's Puffy Tumor: An Uncommon Clinical Entity. *Case Rep Pediatr*. 2012;2012:386104.
5. Leong SC. Minimally invasive surgery for pott's puffy tumor: is it time for a paradigm shift in managing a 250-year-old problem? *Ann Otol Rhinol Laryngol*. 2017;126(6):433-437.
6. Bozdemir K. Treatment of Pott's Puffy tumor with balloon sinuplasty: report of three cases. *Turk J Ear Nose Throat*. 2012;22(6):342-347.
7. Adejumo A, Ogunlesi O, Siddiqui A, Sivapalan V, Alao O. Pott puffy tumor complicating frontal sinusitis. *Am J Med Sci*. 2010;340(1):79.
8. Shin JW, Choi IG, Jung SN, et al. Pott puffy tumor appearing with a frontocutaneous fistula. *J Craniofac Surg*. 2012;23(2):158-160.
9. Parida PK, Surianarayanan G, Ganeshan S, Saxena SK. Pott's puffy tumor in pediatric age group: A retrospective study. *Int J Pediatr Otorhinolaryngol*. 2012;76(9):1274-1277.
10. Blochowiak K, Kamiński B. Combined aplasia of frontal and sphenoid sinuses with hypoplasia of the maxillary sinus. *Eur J Clin Exp Med*. 2018;16(2):155-158.
11. Zylka S, Bieł S, Kamiński B, et al. Epidemiology and clinical characteristics of the sinonasal malignancies. *Otolaryngol Pol*. 2008;62(4):436-441.
12. Podolsky-Gondim GG, Santos MV, Carneiro VM, Augusto LP, Neto RD, de Oliveira RS. Neurosurgical Management of Pott's Puffy Tumor in an Obese Adolescent with Asthma: Case Report with a Brief Review of the Literature. *Cureus*. 2018;10(6):e2836.